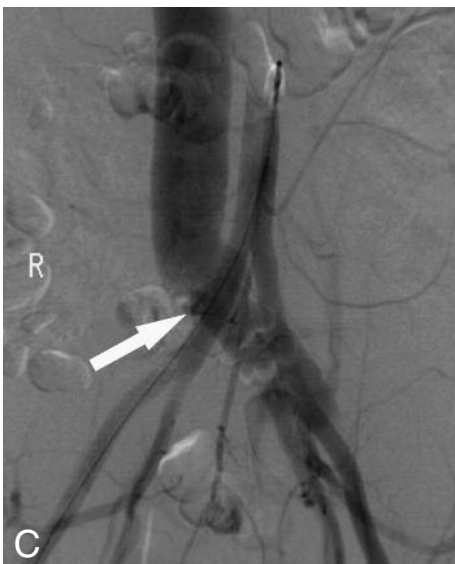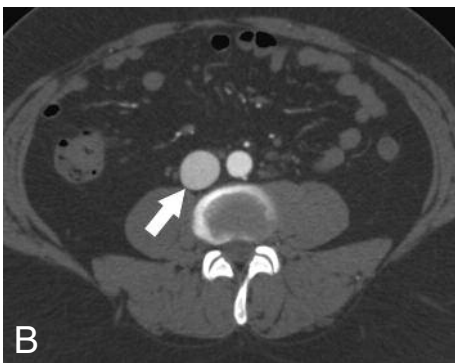
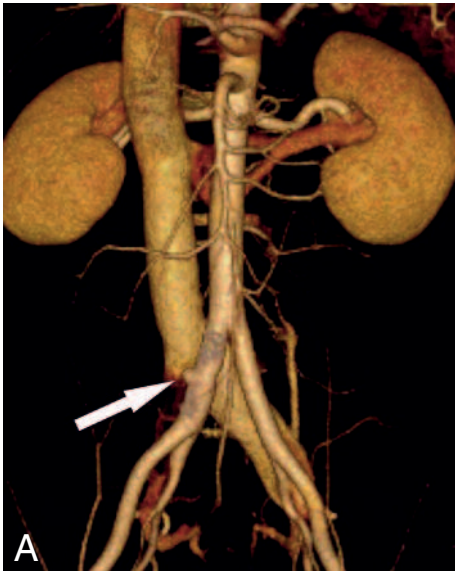


## IMAGES IN CLINICAL RADIOLOGY



### *Re-appearance of an ilio-ilio arteriovenous fistula after endovascular stent grafting demonstrated on MDCT*

R. Killeen, G. McNeill, W. Torreggiani<sup>1</sup>

A 27-year-old male patient presented 3 years ago with a fistula between the right common iliac artery and the left common iliac vein which developed after lumbar disk surgery. The fistula was successfully treated with placement of an endovascular stentgraft in the proximal right common iliac artery at that time. Annual follow-up abdominal computed tomography (CT) was performed. Three years after treatment an arterial phase CT demonstrated redevelopment of the fistula (Fig. A). A small outpouching (4 mm) from the right common iliac artery is evident extending towards the left common iliac vein at the site of fistula formation which was at the mid level of the stentgraft with contrast opacifying the inferior vena cava (IVC) and extending down a distended left common iliac vein consistent with arteriovenous fistula (AVF). Axial CT (Fig. B) shows contrast enhancement of the infrahepatic IVC (straight arrow) which should not occur during arterial phase unless there is an AVF. The patient's conventional angiogram performed at the time of initial diagnosis three years earlier is presented for comparison (Fig. C). This image demonstrates contrast traversing from the right common iliac artery to the left common iliac vein with distension of the IVC typical of an AVF.

#### *Comment*

AVF formation associated with lumbar disk surgery is rare and was first reported by Linton and White in 1945. Repair of AV fistulas is recommended because they may lead to significant shunt flow, congestive cardiac failure and venous hypertension, although some patients remain asymptomatic. Conventional treatment options include direct open surgical repair or surgical bypass grafting but surgical mortality rates vary from 9-34%. Endovascular stentgraft placement has been advocated by several authors as a minimally invasive alternative with low morbidity and mortality. It is unclear at this time what the rate of recurrence of AV fistula is in patients who undergo endovascular treatment and this cohort need to be closely followed with imaging to ensure continued exclusion of the fistula. Recurrent fistula formation may be treated with open repair, graft removal and extra-anatomic bypass or with insertion of a custom made stent-graft placed endovascularly to exclude the fistula. In the above case, follow-up CT at 6 months demonstrated no interval change in the appearances and given the absence of symptoms it was felt at multidisciplinary team meeting that conservative management with further follow-up CT imaging was the best approach.

1. Department of Radiology, Adelaide and Meath Hospital Incorporating the National Children's Hospital, Dublin, Ireland.