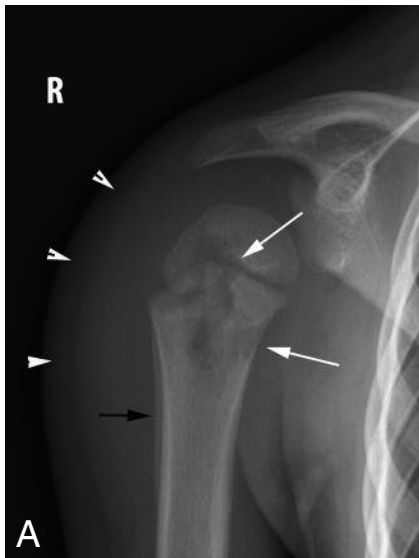


## IMAGES IN CLINICAL RADIOLOGY



### Acute osteomyelitis

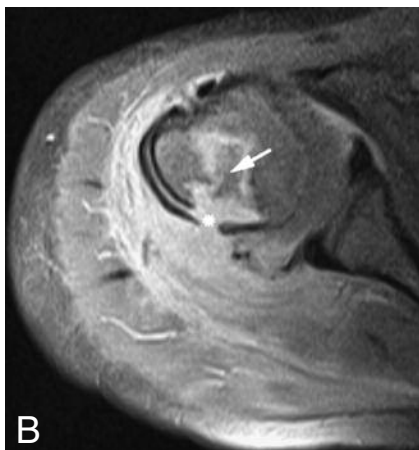
M.I. Wessels<sup>1,2</sup>, M. Baeyaert<sup>1</sup>, J.-L. Termote<sup>1</sup>, F.M. Vanhoenacker<sup>2,3</sup>, A.M. De Schepper<sup>2</sup>, P.M. Parizel<sup>2</sup>

A 4-year-old boy was referred to our department of radiology because of pain in the right shoulder for a few days. Fever had been present for a few weeks before the onset of pain. A radiograph of the right shoulder (Fig. A) showed an ill-defined osteolytic lesion in the proximal diaphysis and metaphysis with extension through the growth cartilage (white arrows), periosteal reaction (black arrow) and soft tissue swelling (short arrows).

Axial fat-suppressed intermediate-weighted MR images (Fig. B), revealed marrow edema (high signal intensity) surrounding a focus of intermediate signal intensity (black arrow), focal cortical breakthrough (cloaca) (asterisks) and surrounding soft tissue edema. After administration of gadolinium-contrast, there was rim enhancement of the bone lesion (white arrow) on the coronal fat-suppressed T1-weighted MR Images (Fig. C). There was also associated soft tissue enhancement.

Based on the imaging findings, the diagnosis of acute hematogenous osteomyelitis was made.

After intravenous antibiotics and oral antibiotic treatment for several weeks, radiographs after one, three and six weeks showed gradual regression of the radiographic abnormalities.



#### Comment

Osteomyelitis consists of an infection of the bone and bone marrow. Hematogeneous spread is the most frequent route of contamination. Acute hematogeneous osteomyelitis is more common in the pediatric patient compared to chronic posttraumatic osteomyelitis in the adult patient.

Symptoms worsen gradually over several days to a week. Initial symptoms, such as malaise and low-grade fever, may be nonspecific and are usually associated with those of bacteremia. Other symptoms include local bone pain, reduced movement of the affected area and local swelling. The long bones of the femur, tibia and humerus are most often involved. Laboratory tests reveal elevated sedimentation rate, C-reactive protein, and white cells count.

The prevalence of acute osteomyelitis in children varies between 1/1000 to 1/5000. It is twice as common in males as females.

*Staphylococcus aureus* is the most common causative organism.

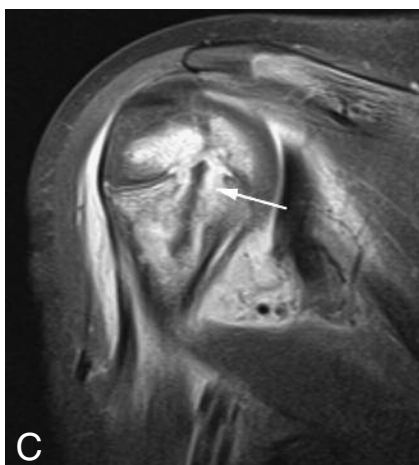Before puberty, the infection starts at the metaphysis. Bacteria may be trapped in the metaphyseal nutrient vessels. Rise in intramedullary pressure due to inflammation and edema leads to local tissue necrosis and breakdown of the trabecular bone structure. Spread of infection occurs along the Haversian canals through the cortex and beneath the periosteal layer. Fragments of necrotic bone may become isolated within the medullary bone (sequestrum).

Conventional radiography is often insensitive for early depiction of osteomyelitis. Subtle soft tissue swelling may be seen within 3 days after infection, but bone destruction and periosteal reaction is delayed for a period of 7 days to 2 weeks.

MR is the preferred modality for early detection and evaluation of local extension of osteomyelitis. Characteristic findings are bone marrow and soft tissue edema, intramedullary, subperiosteal and soft tissue abscess formation, cloaca (cortical breakthrough), and sequestration. After contrast administration there is enhancement of the affected areas with peripheral enhancement in abscesses and sequestrum. Ultrasound may identify subperiosteal fluid collections. The advantage of ultrasound is that sedation or anesthesia is not required and abscess or fluid collections can be aspirated in a single procedure.

Treatment of osteomyelitis consists of intravenous antibiotics or – if unsuccessful – surgical debridement with placement of antibiotic pearls.

The prognosis, with early recognition and prompt treatment, is good.



1. Department of Radiology, Heilig Hart Ziekenhuis, Lier, 2. Department of Radiology, University Hospital Antwerp, UZA, University of Antwerp, Edegem, 3. Department of Radiology, AZ Sint-Maarten, Duffel-Mechelen, Duffel, Belgium.