

## PNEUMOCYSTIS CARINII PNEUMONIA IN A HIV-POSITIVE PATIENT

A.H.M. van Heese<sup>1</sup>, G.A. Risseeuw<sup>2</sup>

**Key-word: Pneumonia**

**Background:** A 38-year-old man, without significant medical history, was referred to the hospital with weight loss, fatigue, night sweat, non-productive coughing and aphthae in the mouth. Physical examination displayed a cachectic man with small lymph nodes palpable in the supra-clavicular region. Auscultation of heart, lungs and abdomen displayed no abnormalities. Blood examination revealed Hb of 5.4 mmol/l, erythrocyte sedimentation rate of 107 mm/h and leukocyte count of  $6.0 \times 10^9/l$ .

Additional blood examination showed a IgA of 4.2 g/l and revealed that the patient was HIV-1 positive, but seronegative for hepatitis B, hepatitis C, lues and tuberculosis.

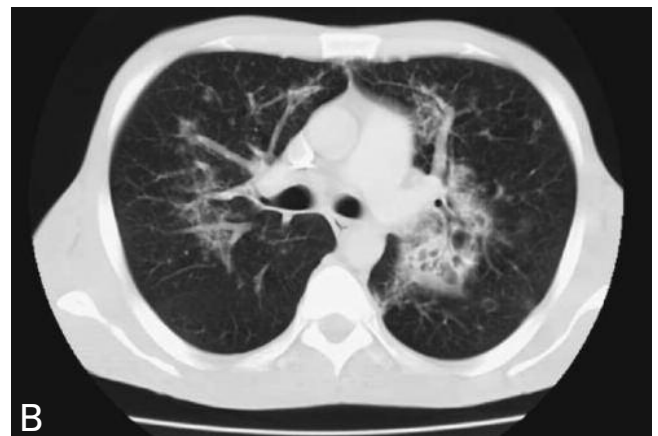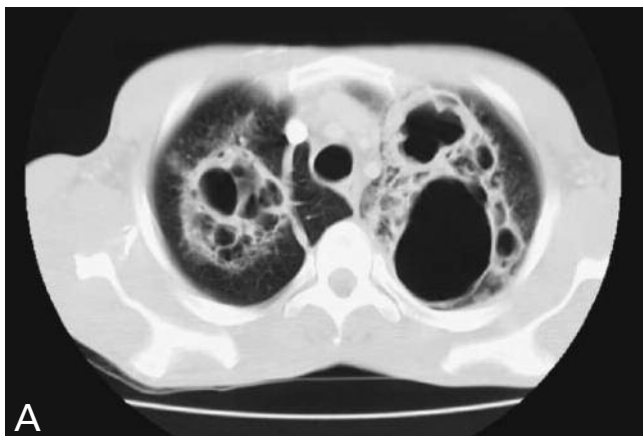

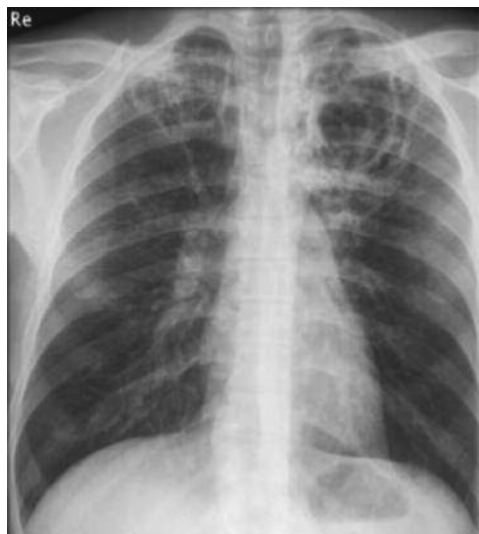
Fig.  $\frac{1}{2A \quad 2B}$

### Work-up

On conventional chest radiograph (Fig. 1), on the top of the lungs there are cavities of different wall-thickness without fluid.

CT scan of the thorax (Fig. 2) includes a section at the level of the top of the lungs (A) on which bilaterally cavitating lesions with septation are visible. Section at hilar level (B) demonstrates little round opacities with central cavitation and areas with interstitial infiltration in both lungs.

### Radiological diagnosis

Bronchoalveolar lavage was performed. Based on the chest X-ray findings, the CT abnormalities and the bronchoalveolar lavage, *Pneumocystis carinii pneumonia* was diagnosed in a HIV-positive patient.

Treatment was started with co-trimoxazol and an anti-retroviral medicine.

### Discussion

*Pneumocystis carinii pneumonia* (PCP) or *P. jiroveci*, is the most common opportunistic infection in HIV patients since the 1980's. PCP is also associated with lymphoreticular malignancies and immunosuppressive therapy.

The symptoms are fever, non-productive cough and progressive dyspnea. Patients may also have weight loss, fatigue and thoracic pain. In 50% of the patients, lung auscultation is normal.

The classic radiographic abnormalities are a ground-glass pattern, interstitial infiltrates and thin walled cysts or cavities. Atypical appearances include lobar or segmental abnormality, pneumothorax, pleural effusion, lymphadenopathy, nodules, apical consolidation or a normal chest radiograph.

The precise pathogenesis of the abnormalities is unknown but they may be due to tissue necrosis, check-valve obstruction, endobronchial invasion of PCP or result from the cytotoxic effect of HIV on the lungs.

In HIV patients with interstitial infiltrates, ground-glass pattern and cavitation in the lungs, one should consider fungal, mycobacterial or pyogenic infections, tuberculosis or Kaposi's sarcoma as differential diagnosis.

One has to be aware of the fact that in patients with coughing or dyspnea, with normal lung auscultation and normal chest radiograph, it may be necessary to make a chest CT scan to visualize the presence of abnormalities that will point out a diagnosis, so that treatment can be started.

### Bibliography

1. Hartman T.E., Primack S.L., Müller N.L., et al.: Diagnosis of thoracic complications in AIDS: Accuracy of CT. *AJR*, 1994, 162: 547-553.
2. Klein J.S., Warnock M., Webb W.R., et al.: Cavitating and Noncavitating Granulomas in AIDS patients with *Pneumocystis pneumonitis*. *AJR*, 1989, 152: 753-754.