

## BILATERAL MUCOID DEGENERATION OF THE POSTERIOR CRUCIATE LIGAMENTS

A.P. Parkar<sup>1</sup>, F.M. Vanhoenacker<sup>2,3,4</sup>, M.E. Adriaensen<sup>5</sup>

**Mucoid (myxoid) degeneration of the anterior cruciate ligament (ACL) is well documented and well known. Mucoid degeneration of the posterior cruciate ligament (PCL) has been reported, but is rare in comparison. The changes may be subtle and may be missed if one is not aware of the diagnosis. As in the ACL, degeneration may cause pain and discomfort. Recognition of the pathology and correct diagnosis is important for the patient and referring physician, as this may have an impact on the therapeutic strategy. We present a case of mucoid degeneration of both PCLs, which to the best of our knowledge has not been published before in the medical literature, as a probable cause of knee pain due to habitual kneeling.**

**Key-word:** Knee, ligaments, menisci, and cartilage.

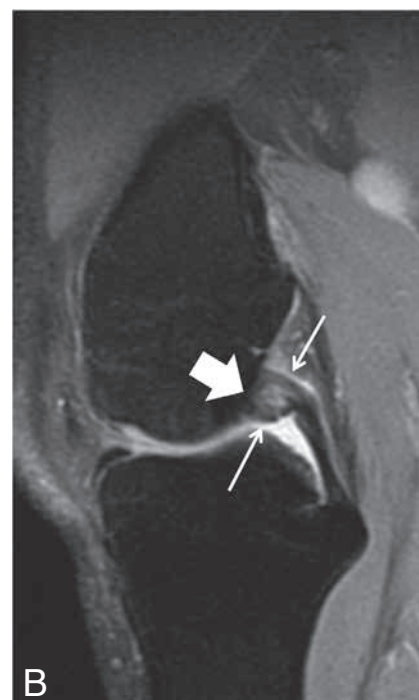
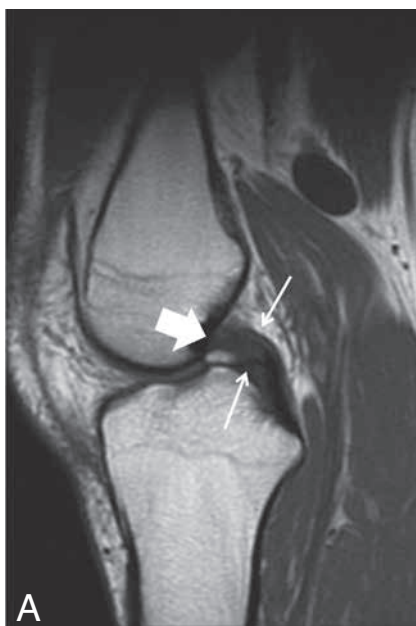
Mucoid (or myxoid) degeneration of the anterior cruciate ligament (ACL) is well documented and a well known entity, however the etiology is still unknown (1, 2). When symptomatic, patients present with pain and reduced range of movement (2). Instability is rare (3). Mucoid degeneration of the ACL is closely related to ganglia of the ACL, and both are considered to be entities originating in the same degenerative process (4), although the imaging findings are clearly different. The “celery stalk” sign in the ACL on Magnetic Resonance Imaging (MRI) refers to subtle, linear, low signal intensity fibers running parallel to the long axis of an otherwise high signal intensity ACL on T2-weighted images (2). Ganglion cysts of the ACL are well delineated masses which arise from the ACL and have high signal intensity on T2-weighted images. They may be lobulated and/or multilocular (4).

Mucoid degeneration and ganglion cysts of the posterior cruciate ligament (PCL) have also been reported, but are rare in comparison to occurrence in the ACL (5, 6).

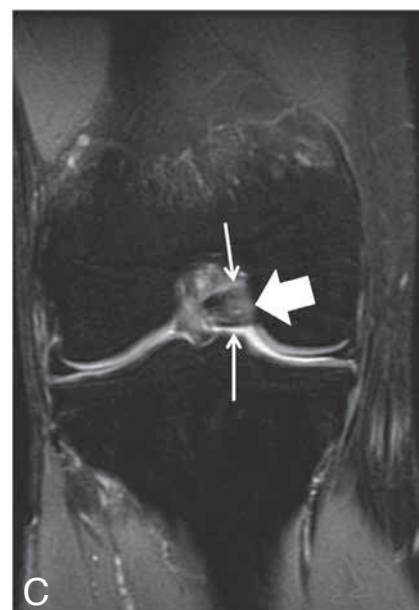The purpose of this case is to discuss the imaging features of a rare case of bilateral mucoid degeneration of the PCL in a young male as a potential cause of pain during kneeling.

### Case report

A 30-year-old electrician presented with bilateral knee pain. There

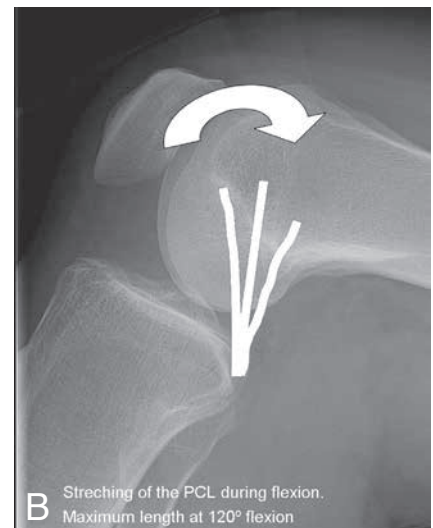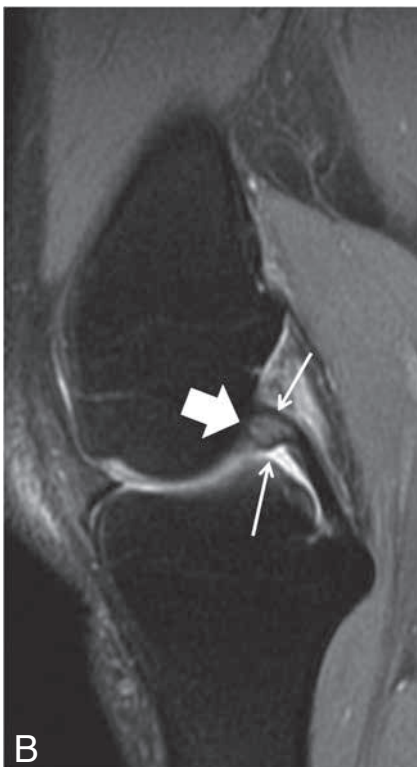
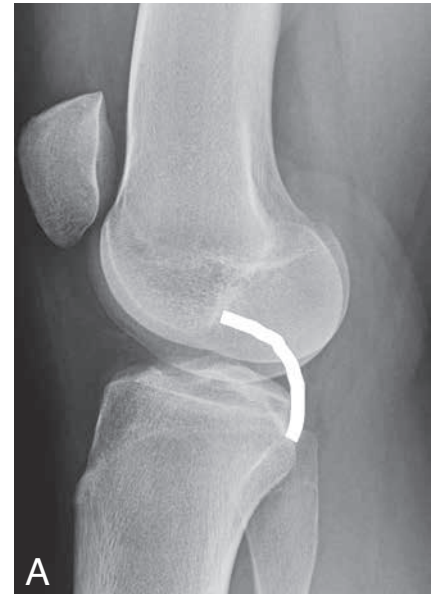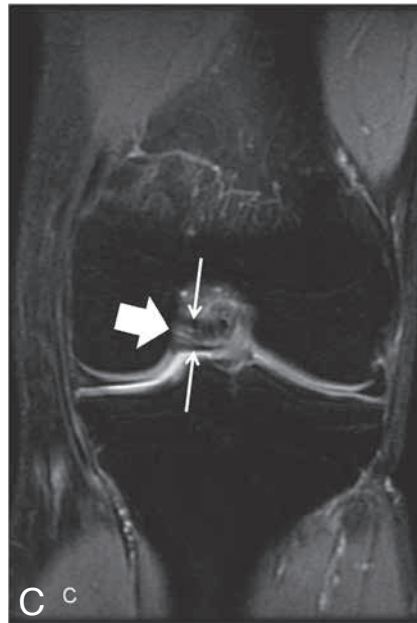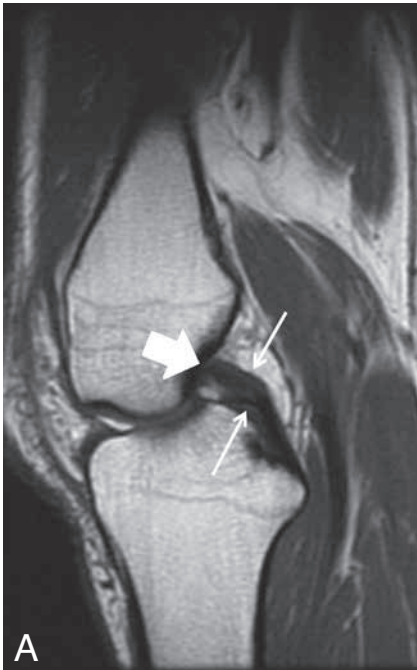


*Fig. 1.* — Sagittal T1-weighted image (A) and sagittal fatsuppressed T2-weighted image (B) of the right knee shows altered signal intensity in the central part of the PCL (bold arrow) with intact peripheral fibres (small arrows). This is also easily recognized on the coronal fatsuppressed T2-weighted images (C).



was no history of trauma. He worked on his knees for hours at a time on a regular basis. The position while working was in maximum flexion in the knee joint, often with the full weight resting on his ankles. The

*From:* 1. Department of Radiology, Haralds plass Deaconess Hospital, Ulriksdal 8, 5009 Bergen, Norway, 2. Department of Radiology, AZ Sint-Maarten Duffel-Mechelen, 3. Department of Radiology, Antwerp University Hospital, Edegem, 4. University of Ghent, Faculty of Medicine and Health Sciences, Ghent, Belgium 5. Department of Radiology, Atrium Medical Center Parkstad, Heerlen, The Netherlands.  
*Address for correspondence:* Prof Dr F.M. Vanhoenacker, M.D., Dept. of Radiology, AZ Sint-Maarten, Duffel-Mechelen, Rooienberg 25, B-2570 Duffel, Belgium.



**Fig. 2.** — Sagittal T1-weighted image (A) and sagittal fatsuppressed T2-weighted image (B) of the left knee shows altered signal in the central portion of the PCL (bold arrows), with intact peripheral fibres (small arrows). Again, this is also easily recognized on the coronal fatsuppressed T2-weighted image (C).

MRI showed bilateral thickening of the proximal PCL's, with low signal intensity on T1-weighted images and a high signal intensity centrally on T2-weighted images. In addition, intact fibers were seen in the periphery (Fig. 1-2), resembling the celery stalk sign similar to mucoid degeneration of the ACL. Both sides were equally affected on MRI. There were no other pathological findings detected in either knee, which could explain the bilateral knee pain. Based on the imaging findings, the diagnosis of bilateral mucoid degeneration of the posterior cruciate ligament was made.

The patient has since been examined by an orthopedic consultant, but because of the relatively minor symptomatology, a wait-and-see policy was preferred over a surgical decompression of the lesions.

### Discussion

Mucoid degeneration of the PCL is relatively rare and therefore it is less known than its counterpart involving the ACL (5). The etiology is uncertain, but previous trauma may be the cause of development of mucoid degeneration or cysts in the PCL (6). In the largest reported series simultaneous presence of mucoid degeneration in

pain worsened when he got up from this kneeling position, and persisted up to 15 minutes after this movement before it subsided again. In recent months he had experienced increasing pain while kneeling and sitting in this position. The clinical examination was unremarkable. He had no signs of instability or "give way" of the knee. Radiographs were reported normal. The patient was then referred to perform MRI of both knees.

**Fig. 3.** — Changes in the length of the PCL during flexion. The PCL drawn on a lateral radiograph (A) of the knee in full extension (unrelated patient). The PCL is in neutral position here.

During flexion (B), here at 90°, the PCL stretches, and continues to a maximum at about 120°, before it then decreases in length again (designed after reference 8).

both ACL and PCL, or concomitant presence of mucoid degeneration and ganglion cysts in a ligament have been described, but to the best of our knowledge no case of bilateral, isolated mucoid degeneration of the PCL has been reported previously.

In our case, the electrician sits on his knees with a high degree of flexion in the knee joint or kneels for a long period during the day. The degree of knee flexion was between 90°-130°, a position in which the anterior part of the PCL is stretched

most during knee movement (7, 8) (Fig 3). We suggest therefore that prolonged and repetitive stretching of the PCL could be the cause of degeneration in our patient.

Diagnosis is usually made on MRI findings, although histology is necessary for definitive diagnosis. In patients with mild symptomatology, such as in our patient, histological confirmation would be unethical as it would submit the patient to an invasive procedure.

Mucoid degeneration is often misdiagnosed as a partial rupture (4). It is important to differentiate mucoid degeneration from a partial tear as the treatment differs. On imaging, at least partial fibre discontinuity in the periphery of the ligament is seen in case of a partial rupture. On the contrary, in mucoid degeneration the peripheral fibres are intact. Isolated PCL tears are normally not surgically treated, and conservative treatment of a partial PCL rupture consists of protective weightbearing and quadriceps muscle rehabilitation. A curettage of degenerative tissue in mucoid degeneration can decompress the ligament and result in symptom

relief (9). However, PCL degeneration may be treated conservatively with restricted joint activity as an alternative option for curettage (10). Thus misdiagnosing mucoid degeneration of the PCL as an isolated partial tear, may deprive the patient of correct treatment.

To conclude, mucoid degeneration rarely occurs in the PCL, and may be bilateral. It is important to distinguish mucoid degeneration of the PCL from partial PCL tears as the treatment could differ between the two pathologies.

## References

1. Fernandes J.L., Viana S.L., Mendonca J.L., Freitas F.M.: Mucoid degeneration of the anterior cruciate ligament: Magnetic resonance imaging findings of an underdiagnosed entity. *Acta Radiol*, 2008, 49: 75-79.
2. Papadopoulou P.: The Celery Stalk Sign. *Radiology*, 2007, 245: 916-917.
3. Hensen J.J., Coerkamp E.G., Bloem J.L., De Schepper A.M.: Mucoid degeneration of the anterior cruciate ligament. *JBR-BTR*, 2007, 90: 192-193.
4. Bergin D., Morrison W.B., Carrino J.A., Nallamshetty S.N., Bartolozzi A.R.: Anterior cruciate ligament ganglia and mucoid degeneration: coexistence and clinical correlation. *AJR*, 2004, 182: 1283-1287.
5. Viana S.L., Fernandes J.L., Mendonça J.L., Freitas F.M.: Diffuse intrasubstance signal abnormalities of the posterior cruciate ligament: the counterpart of the mucoid degeneration of the anterior cruciate ligament? A case series. *JBR-BTR*, 2008, 91: 245-248.
6. See P.P.L., Peh W.C.G., Wong L.Y., et al.: Clinics in diagnostic imaging (129). *Singapore Med J*, 2009, 50: 1102-1108.
7. Pappannagari R., DeFrate L.E., Nha K.W. et al.: Function of posterior cruciate ligament bundles during in vivo knee flexion. *Am J Sports Med*, 2007, 35: 1507-1512.
8. Nakagawa S., Johal P., Pinskerova V., et al.: The posterior cruciate ligament during flexion of the normal knee. *J Bone Joint Surg Br*, 2004, 86: 450-456.
9. Harner C.D., Höher J.: Evaluation and treatment of posterior cruciate ligament injuries. *Am J Sports Med*, 1998, 26 (3): 471-482.
10. Izumi S., Fujimoto E., Sasashige Y., et al.: Ganglion cyst of the posterior cruciate ligament in a 5-year-old: a case report. *Eur Orthop Traumatol*, 2011, 2: 59-61.