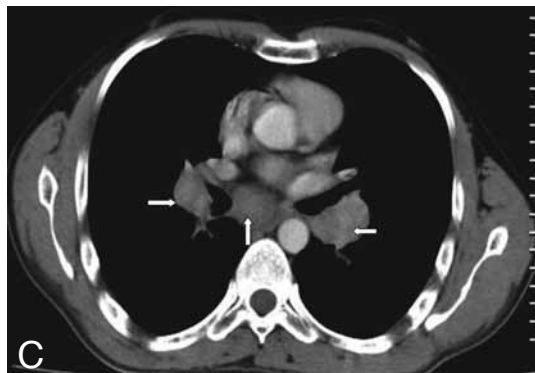
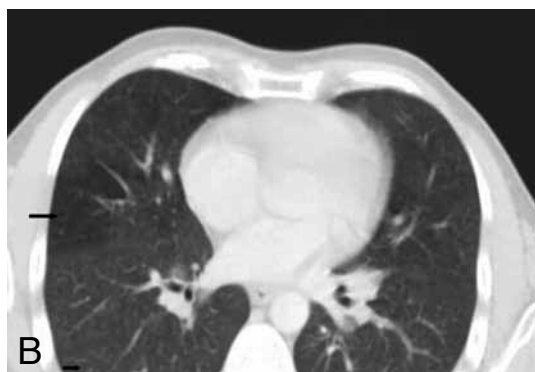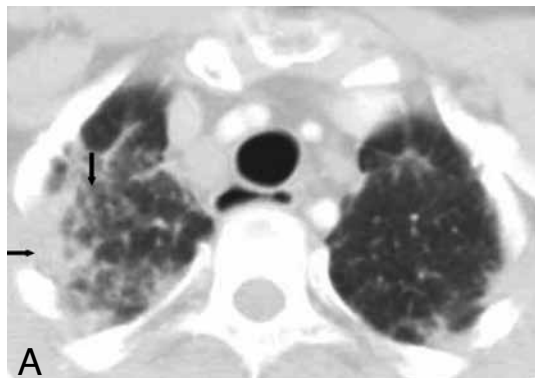


## IMAGES IN CLINICAL RADIOLOGY



### *Denim sandblasters' pneumoconiosis*

M. Apaydin<sup>1</sup>, M. Varer<sup>1</sup>, S. Ayik

A 28-year-old man with long standing dyspnea for 4 years and a history of dry cough, sweating and loss of weight was admitted to the hospital. Physical examination showed fine crackles at the end of inspiration. The laboratory tests revealed increased low density lipoprotein level with slight increase in erythrocyte sedimentation rate. Sputum smears for blood culture and tuberculosis were negative. He was referred to the radiology department for imaging studies. Chest radiography revealed bilateral reticulonodular infiltrates in upper and middle zones. High resolution computed tomography showed bilateral diffuse intralobular micronodules in upper and mid lung zones with interlobular septal lines also bilateral pleural thickening was seen (A). Right middle lung zone showed hyperaeration (B). Also he had bilateral hilar, right paratracheal, prevascular and subcarinal lymphadenopathies (C). He had been working in producing sandblasted denims for 10 years. The diagnosis was based on clinical history, occupational exposure to silica dust, and chest x-ray findings after other possible diagnoses were ruled out.

#### *Comment*

Denim sandblasting changes the color of the denim and gives worn appearance. Quartz is used for denim sandblasting and cause the most common form of pneumoconiosis called silicosis by inhaled dust containing crystalline silica. It easily develops in small and unventilated unhealthy working place conditions with extended exposure to tiny sand particles. Silicosis is untreatable and causes death by impairing general health status. It can be seen in underdeveloped as well as developed countries. Mining, drilling, construction, pottery making are the most known etiologic factors. Also, it can be accompanied with autoimmune disease. Tuberculosis is a frequent complication of this disease and there is a strong link between lung cancer and silicosis. Three main clinical presentations were described; acute/silicoproteinosis, classic, accelerated types. Radiologic findings depends the stage and type of the disease. The most common presentation is classic chronic silicosis like our case. These patients are usually become clinically and radiologically symptomatic after 10-20 years of chronic silica exposure.

Smooth nodular infiltrations, interlobular and intralobular septal thickening, axial interstitium thickening, ground glass consolidation, honeycombing, pleural thickening, low-attenuated areas, mediastinal lymphadenopathies are the most detected abnormalities on CT.

Denim sandblasters' silicosis is a rare cause of pneumoconiosis. There is no cure for this preventable environmental disease. So it is very important to be aware of clinical and radiological findings of denim sandblasters' silicosis.

1. Department of Radiology, 2. Sleep and Chest Disorders Unit, Izmir Atatürk Education and Research Hospital, Izmir, Turkey.