

INTESTINAL CARCINOID TUMOR IN DYSPNEIC PATIENT

D. Bijdevaate, F. Willemsen¹

Key-word: Carcinoid

Background: A 61-year-old man was evaluated for progressive dyspnea d'effort and peripheral edema in the legs. Laboratory findings revealed disturbed liver functions. Initially an ultrasonography of the abdomen and a CT scan of the abdomen and thorax following intravenous administration of contrast medium were performed.

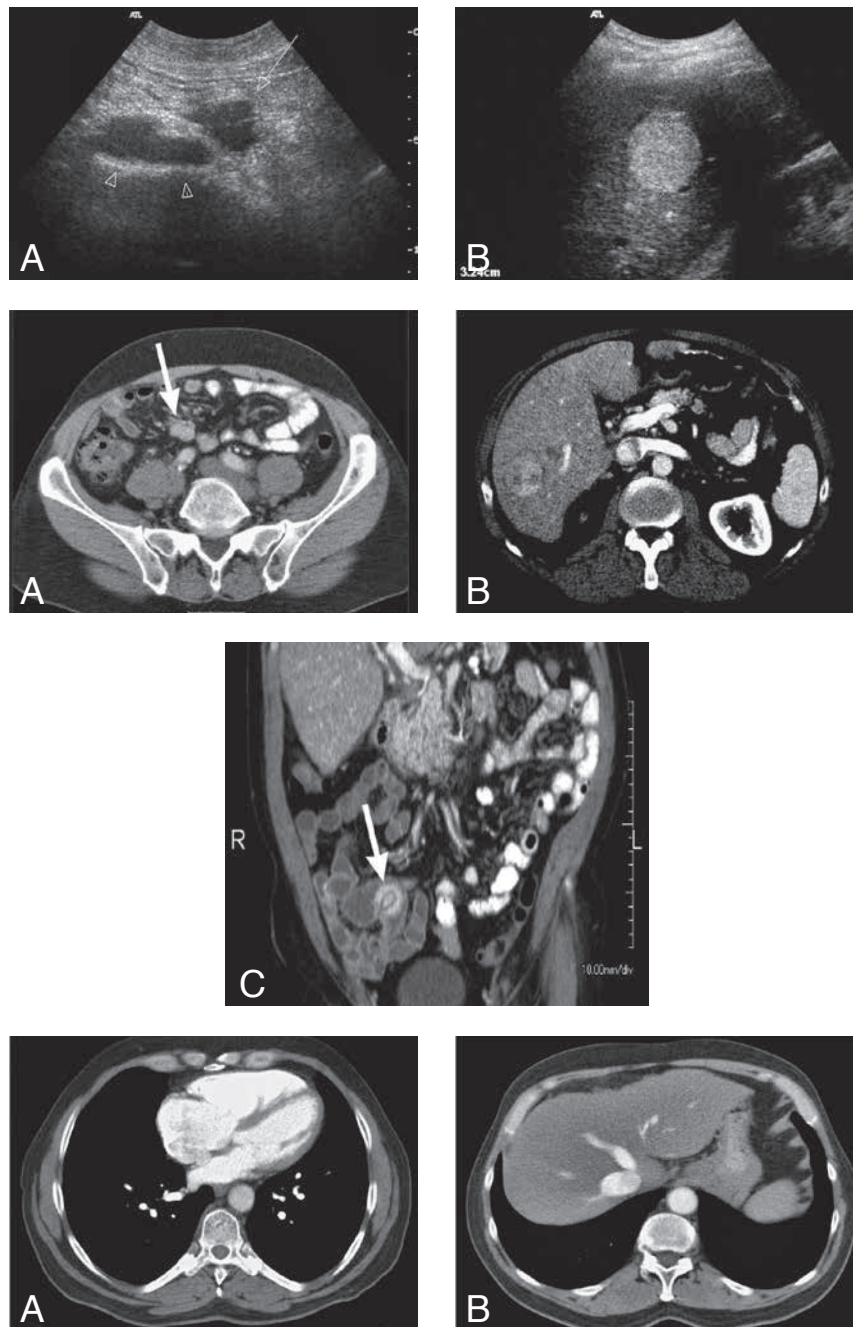


Fig.

1A	1B
2A	2B
2C	
3A	3B

1. Department of Radiology, Erasmus Medical Centre, Rotterdam, The Netherlands

Work-up

Ultrasonography of the abdomen (Fig. 1) includes a section at the level of the right lower quadrant (A) which shows a hypoechogenic mass (arrow) in the mesentery anterior to the iliac vessels (arrowheads) and a section through the liver (B) which demonstrates one of the multiple hyperechogenic lesions in the liver.

Contrast-enhanced CT scan of the abdomen (venous phase) (Fig. 2) shows on section at the level of the right iliac fossa (A) a hypervascular enhancing lesion in the mesenterium anterior to the iliac vessels (arrow). Section through the liver (B) demonstrates a nonhomogeneous, strongly enhancing lesion within the right liver lobe. Multiplanar reformatted image (MPR) in the coronal plane (C) visualizes a strongly enhancing lesion in the preterminal ileum with "hairpin turn" configuration (arrow).

Contrast-enhanced CT scan of the thorax (arterial phase) (Fig. 3) shows on section through the heart (A) a markedly enlarged right atrium and right ventricle. Section through the dome of the liver (B) demonstrates backflow of contrast medium into dilated middle liver vein.

Radiological diagnosis

Based on the ultrasonographic and CT findings, the diagnosis of an *intestinal carcinoid tumor* was made. Furthermore, there were liver metastases and signs of right heart failure as a manifestation of the carcinoid syndrome.

The diagnosis was confirmed by laboratory findings (chromogranine A), and 5-HIAA secretion in the urine. Right heart failure was confirmed by cardiac ultrasonography.

Discussion

Carcinoid tumors were originally described by Langhans in 1867. They were referred to as 'karzinoide' ("carcinoma-like") by Oberndorfer in 1907 because these tumors were less aggressive than most gastro-intestinal carcinomas.

Carcinoid tumors are a group of well-differentiated neuro-endocrine tumors that arise from the endocrine cells in the gut. Depending on the histological subtype and secretion of hormone or peptide, the tumors can cause specific symptoms.

Occurring in about 1.9 per 100,000 persons annually worldwide, carcinoid tumors are relatively uncommon neoplasms. Mean age of the patients is 61.4 years. Carcinoids of the ileum and jejunum equally affect men and women.

Accounting for about 67% of all cases, carcinoids most frequently occur in the gastrointestinal tract, followed by the tracheobronchial system in about 25%. Midgut carcinoids are considered the classic form of the disease (40-50%).

These tumors are slow growing and even in the presence of metastasized disease patients may survive for several years. Five-year survival is 70-80%.

On medical imaging a carcinoid in the small bowel wall may show as a focal enhancing mass with a kink or curvature, causing the so-called "hairpin-turn". The latter is the result of infiltration and fibrosis and is shown rather characteristically in the presented case (Fig. 2c). Liver and (local) mesenterial metastases are common and typically are hypervascular and hence strongly enhancing lesions.

Patients develop symptoms due to local tumor effects or metastatic disease. Often the disease is detected because of the metastatic side-effects.

In the presented case, the predominant symptom was dyspnea d'effort as a result of right-sided heart failure due to a carcinoid tumor with diffuse metastases. Carcinoid heart disease is characterized by plaque-like fibrous deposits on the right heart valves and endocardium leading to valvular dysfunction and right cardiac failure.

Bibliography

1. Levy A.D., Sobin L.H.: Gastrointestinal Carcinoids: Imaging Features with Clinicopathologic Comparison. *RadioGraphics*, 2007, 27: 237-257.
2. Scarsbrook A.F., et al.: Anatomic and functional imaging of metastatic carcinoid tumors. *RadioGraphics*, 2007, 27: 455-476.