

## LEFT VENTRICULAR DIVERTICULUM: INCIDENTAL FINDING ON DUAL SOURCE CARDIAC CT

Y. De Bruecker<sup>1</sup>, L. Janssen<sup>1</sup>, F. De Somer<sup>1</sup>, K. Boeren<sup>1</sup>, B. Ector<sup>2</sup>, L. Janssens<sup>2</sup>, D. Perdieus<sup>1</sup>

The purpose of this retrospective study is to describe the prevalence, size and location of left ventricular (LV) diverticulum-diverticuli on cardiac dual source CT. Dual source computed tomography cardiac angiography (DS CTCA) was performed in 482 patients. Where literature states their rare occurrence, this retrospective study demonstrates the fairly common finding of incidental LV diverticulum on DS CTCA examinations. LV diverticuli were found incidentally in 20 out of 482 patients (4.1%), a substantially higher incidence than previously reported. Although diverticuli were most common along the inferoseptal wall (45%) they also occurred in all parts of the left ventricular wall. Multiple diverticuli were found in 30% of patients. Dimensions of the LV diverticuli varied enormously. LV diverticuli are reported to be frequently associated with other congenital anomalies. Complications ranging from sudden death and heart failure to embolic events have been described in literature. No relevant associated anomaly or complication was present in the studied 20 patients. Our data support the hypothesis that LV diverticuli, incidentally found in adulthood, follow a benign course and can be managed conservatively. More knowledge is however required to understand history and prognosis about this condition.

**Key-words:** Heart, ventricles – Heart, CT.

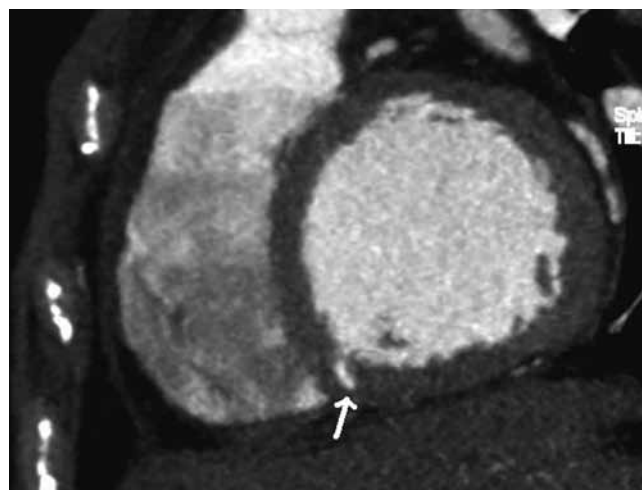
Left ventricular (LV) diverticuli are considered to be a rare congenital disorder. The prevalence of congenital ventricular diverticuli was reported to be 0.4% in an autopsy series of patients who had died as a result of cardiac disease and only 0.26% in a general population referred for cardiac catheterisation (1). Less than 100 cases have been reported in the English literature (2).

Computed tomography cardiac angiography (CTCA) has emerged as a robust and accurate tool for the non-invasive evaluation of coronary artery disease (3, 4). CTCA further provides important new noninvasive insights into subtle details of cardiac morphology. A rather unexplored area is that of variants of the left ventricle. The goal of this study is to determine the prevalence, imaging characteristics and anatomic locations of LV diverticuli on dual source (DS) CTCA (Definition, Siemens Medical Solutions). The potential clinical relevance of the presence of these structures is discussed.

### Materials and methods

ECG-gated cardiac CT imaging was performed in 542 consecutive patients for a period of 14 months and was retrospectively reviewed. All imaging was performed with a dual source CT (Definition, Siemens Medical Solutions) (330 milliseconds gantry rotation time, 83 ms temporal

resolution). Image acquisition was performed during a single breath hold. Imaging parameters included a slice collimation of 64 x 0.75 mm, a tube voltage of 100-120 kV and an effective tube current of 750-850 mAs. Patients were included in the study if intravenous contrast had been administered. Injection consisted of 80-110 ml of non-ionic contrast material (Iomeron 400, Bracco), administered at a rate of 5.0 mL/s by a power injector. Depending on heart rate, patients were scanned prospectively or retrospectively.



*Fig. 1.* – MIP short axis view shows a basal inferoseptal located diverticulum (arrow). Involvement is more than half of the myocardial thickness on this diastolic image.

Because diverticuli can be compressed during the systolic phase, search for LV diverticuli was done on diastolic images. Multiplanar reconstructions as well as maximum intensity projections were generated. Diverticuli were differentiated from trabeculations using following criterion: if involvement was less than half of the myocardial thickness on diastolic images, it was considered a trabeculation (5) (Fig. 1). Two investigators reviewed the images retrospectively via a consensus reading.

Presence and size of LV diverticuli were recorded. The prevalence of LV diverticuli was calculated. They were measured in mediolateral length, anteroposterior width and cranio-caudal height. Ostium caliber of these diverticuli was also measured.

*From:* 1. Department of Radiology, 2. Department of Cardiology, Bonheiden Imelda Hospital, Bonheiden, Belgium.

*Address for correspondence:* Dr Y. De Bruecker, M.D., Department of Radiology, Bonheiden Imelda Hospital, Imeldalaan 9, 2820 Bonheiden, Belgium.  
E-mail: yves.de.bruecker@imelda.be

*Table 1. — Clinical and imaging characteristics of 20 patients with left ventricular diverticuli.*

	age	sex	Nb. <sup>2</sup>	location	Dimensions <sup>1</sup> (cm)	Ostium (cm)	Associated findings
1	34	M	2	Mid inferoseptal Mid inferoseptal	0.8 x 0.2 x 0.6 0.5 x 0.2 x 0.7	0.4 0.2	None
2	50	M	1	Basal inferoseptal	1.0 x 0.2 x 0.5	0.2	Accessory left atrial appendage
3	44	F	2	Basal inferoseptal Basal inferoseptal	0.7 x 0.3 x 0.8 1.0 x 0.5 x 0.9	0.2 0.4	Chronic pericarditis
4	64	F	1	Mid inferoseptal	1.2 x 0.4 x 1.2	0.6	None
5	22	F	1	Basal inferoseptal	0.9 x 0.2 x 0.7	0.2	None
6	86	F	1	Apical inferior	0.9 x 0.6 x 1.6	0.3	None
7	81	F	1	Apical septal	1.2 x 0.4 x 1.0	0.8	CT prior to PAVI <sup>3</sup> implacment
8	73	M	1	Mid anteroseptal	1.4 x 0.3 x 0.9	0.4	Obstructive lesion of the circumflex artery
9	56	M	2	Mid anteroseptal Mid anteroseptal	1.5 x 0.3 x 1.4 0.6 x 0.4 x 0.6	0.6 0.4	None
10	48	F	1	Mid anteroseptal	0.9 x 1.0 x 0.9	0.3	None
11	45	M	1	Basal inferoseptal	1.0 x 0.3 x 0.5	0.5	Accessory left atrial appendage
12	67	M	1	Mid septal	0.8 x 0.2 x 0.9	0.4	Accessory left atrial appendage
13	75	F	1	Apical septal	1.0 x 0.4 x 0.3	0.3	None
14	53	F	1	Apical septal	0.6 x 0.6 x 0.4	0.2	None
15	52	F	2	Basal inferoseptal Basal inferoseptal	0.3 x 0.3 x 1.0 0.3 x 0.3 x 1.0	0.2 0.2	Accessory left atrial appendage
16	47	M	3	Mid anteroseptal Mid septal Basal inferoseptal	0.7 x 0.3 x 0.5 0.6 x 0.2 x 0.3 0.5 x 0.2 x 0.5	0.3 0.5 0.2	Accessory left atrial appendage
17	49	F	1	Mid anteroseptal	1.1 x 0.4 x 1.1	1.2	Accessory left atrial appendage
18	67	F	2	Mid anteroseptal Mid septal	0.5 x 0.2 x 0.2 0.6 x 0.2 x 0.2	0.2 0.2	Accessory left atrial appendage
19	63	F	1	Basal inferoseptal	0.6 x 0.3 x 0.4	0.2	None
20	57	M	1	Basal lateral	1.4 x 0.3 x 0.6	0.3	Accessory left atrial appendage

<sup>1</sup> dimensions of diverticuli are given in mediolateral length x anteroposterior width x craniocaudal height.

<sup>2</sup> Nb. = number of diverticuli.

<sup>3</sup> PAVI = percutaneous aortic valve implacment.

The examinations were evaluated for presence of any other cardiac congenital abnormality including left atrial accessory appendages, atrial septum defect, ventricular septum defect. They were also evaluated for presence of any acquired cardiac abnormality including coronary artery disease, aneurysm of the ascending aorta, pericardial disease.

## Results

During the period from December 2008 through January 2010, 542 patients underwent DS CTCA. Indications were: assessment of coronary arteries (459/542), patency of coronary artery bypass grafts (3/542), pre- or postpulmonary vein isolation procedures (62/542) and pre-percutaneous aortic valve implacment (PAVI) (18/542). Coronary calcium score was determined if assessment of coronary

arteries was required. 60 patients presented with high calcium score levels (Agatston score of > 800). No contrast was administered in these patients because too many beam hardening artefacts could be expected to evaluate the coronary arteries. Since evaluation of LV diverticuli requires contrast administration, these patients were excluded from this study.

20 patients out of 482 (4.1%) were found to have LV diverticuli. Table 1 summarizes the clinical and imaging characteristics of these patients. 19 out of these 20 patients were imaged for evaluation of the coronary arteries. One patient was imaged prior to PAVI procedure.

The diverticuli ranged from 0.5 to 1.4 cm in maximum dimension. Ostia of the diverticuli ranged from smaller than 0.2 cm to 1.2 cm.

The patient group consisted of 12 women and 8 men between the ages of 34 and 86.

Most frequent location of these LV diverticuli is the inferoseptal part of the LV wall (9 out of 20 (45%)), but they occur in any location. Fig. 2 demonstrates a mid anteroseptal located LV diverticulum.

Multiple diverticuli were present in 6 out of 20 patients (30%). 5 patients presented with 2 diverticuli and 1 patient presented with 3 diverticuli. When multiple diverticuli were found, they were grouped together except in 1 patient. Fig. 3 shows 2 diverticuli in 1 patient, located in the basal inferoseptal part.

1 patient presented with obstructive atherosclerotic coronary pathology; no significant coronary pathology was found in the other patients. 1 patient was known with chronic recurrent auto-immune pericarditis. 8 patients (40%) presented with left atrial accessory appendages. None of the patients presented with associated atrial or ventricular septal defect. None of the

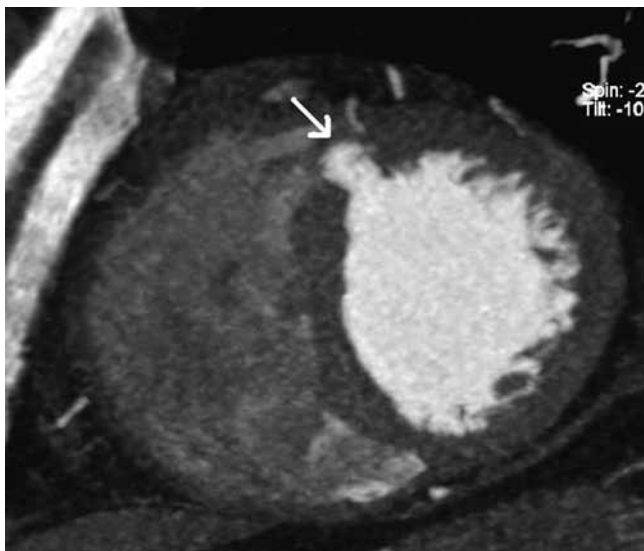

Fig. 2. — MIP short axis view shows an mid anteroseptal located diverticulum (arrow).

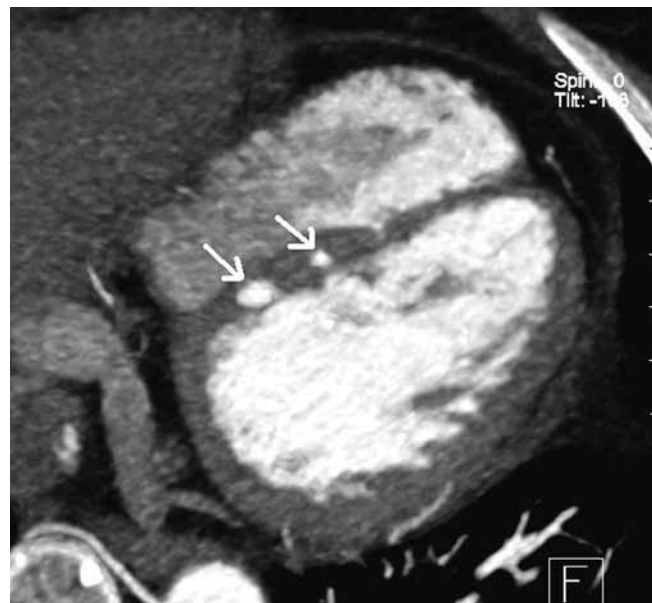


Fig. 3. — MIP horizontal long axis view shows 2 basal inferoseptal located diverticuli (arrows).

patients presented with enlarged ascending aorta. None of these structures revealed the presence of thrombus.

### Discussion

The purpose of this study was to assess the prevalence, size and location of left ventricular diverticula as incidentally observed with DS CTCA.

Literature consists predominantly of a modest number of case reports and clinical series. No typical or pathognomonic ECG changes are known, and specific laboratory tests for the diagnosis are not available. They are usually found incidentally during diagnostic imaging procedures performed for other reasons. LV diverticulum or diverticuli are considered to be rare (1). They have been described as a rare malformation that can occur isolated or in association with other congenital abnormalities such's as Ebstein's anomaly, hypertrophic cardiomyopathy, Cantrell's syndrome (6-8). Apical diverticuli are reported to be frequently (more than 70%) associated with congenital abnormalities (9,10), but none of the 4 patients with apical diverticuli reported in this study revealed this association. None of our reported patients presented with a relevant cardiac abnormality. 8 out of the 20 patients (40%) presented with a non-significant left atrial accessory appendage.

Diverticuli can either be secondary to intrinsic abnormalities in

embryogenesis or acquired in utero, e.g. viral infections or vascular accidents (11). Congenital ventricular diverticuli should be differentiated from other causes of acquired ventricular aneurysms such as those after myocardial infarction, myocardial inflammatory disease such as sarcoidosis or myocarditis, infectious endocarditis or trauma (12). Differential diagnosis with acquired ventricular aneurysms can not be made with certainty based on imaging alone. Often the distinction can only be made with knowledge of cardiac history. According to pathology findings (13), congenital diverticuli can be classified in two types: fibrous or muscular. In our study, we didn't classify the diverticula. Any localized protrusion of the ventricular lumen, with a depth more than half of the muscular wall on diastolic images, was considered to be a diverticulum as done in a similar study by Srichai et al. (5).

Srichai et al. studied the prevalence of LV diverticuli in a cardiac CT population (2.2%, 15 out of 675 patients). The substantially higher prevalence in our study (4.1%) can be explained by better temporal resolution in DS CTCA as only a small percentage of patients were scanned with this technique in the Srichai's study (16.7%, 113 out of 675).

Most common location of diverticuli in our study is the inferoseptal part of the LV (45% of patients (9 out of 20)). This finding corresponds to the literature (5). Our study further

shows that diverticuli can appear in any location of the LV wall. We describe the anteroseptal location of a LV diverticulum in 6 patients which is, to our knowledge, never published in literature before.

Overall dimensions (from smaller than 2 mm to 1.4 cm) and dimensions of the ostia of the studied diverticuli vary enormously. The sizes of ventricular diverticula described in the literature range from as small as 0.5 cm in diameter to as large as 8-9 cm (12).

Several complications have been reported in association with a ventricular diverticulum. Pitol et al. reported a case of a patient with new onset of arrhythmia due to a LV diverticulum at the age of 56 (14). Handler et al. reported a 25-year-old male with heart failure and a LV diverticulum on MRI (15). Bernasconi et al. reported a case of prenatal rupture (16). Bell and Ehmke reported a child with fatal cerebral embolisation (17). Too few cases have been described to find a relation between location and symptomatology. It is generally accepted that larger diverticuli are more prone to be symptomatic (18).

The management of this condition remains unclear and is primarily affected by symptoms and associated malformations. Based on the possible reported complications some authors recommend aggressive surgical treatment (19). Others suggest that the clinical course may be benign and recommend a more

conservative approach (20). All diverticuli described in this study were incidental findings and could not be related to symptomatology. They were managed conservatively with clinical follow-up. It is clear that more knowledge is required to decide upon adequate therapy. Mode of treatment has to be individually tailored and depends on clinical presentation, accompanying abnormalities and possible complications.

Our study has some limitations. Pathology was not available to confirm the diagnosis. Because it was a retrospective study in an almost exclusive coronary setting (just 1 out of 20 patients with LV diverticuli was scanned for pre PAVI procedure), the results can only be related to this group and not to the general population. The potential association with other cardiac and non cardiac abnormalities is not sufficiently assessed and needs to be investigated in future studies. Male to female ratio is 1 to 1.5 in our study but too few patients are included in this study to make any conclusions.

In conclusion, DS CTCA represents a unique tool to assess subtle anatomic cardiac variants. Our data show that left ventricle diverticuli can be incidentally found in more than one twenty-fifth of subjects undergoing DS CTCA. They further support the hypothesis that LV diverticuli, incidentally found in adulthood, follow a benign course. More knowledge is however required to understand prognosis about this condition.

## References

1. Skapinker S.: Diverticulum of the left ventricle of the heart, review of the literature and report of a successful removal of the diverticulum. *Arch Surg*, 1951, 63: 629-634.
2. Cianciulli T.F., Del Carmen Gonzalez Colaso P., Saccheri MC., Lax J.A., Redruello H.J., Guerra J.E., Prezioso H.A., Vidal L.A.: Left ventricular diverticulum, a rare echocardiographic finding: two adult patients and review of the literature. *Cardiol J*, 2009, 16: 76-81.
3. Leschka S., Alkadhi H., Plass A., Desbiolles L., Grünenfelder J., Marincek B., Wildermuth S.: Accuracy of MSCT coronary angiography with 64-slice technology: first experience. *Eur Heart J*, 2005, 26: 1482-1487.
4. Scheffel H., Alkadhi H., Plass A., Vachenaer R., Desbiolles L., Gaemperli O., Schepis T., Frauenfelder T., Schertler T., Husmann L., Grunenfelder J., Genoni M., Kaufmann P.A., Marincek B., Leschka S.: Accuracy of dual-source CT coronary angiography: First experience in a high pre-test probability population without heart rate control. *Eur Radiol*, 2006, 16: 2739-2747.
5. Srichai M.B., Hecht E.M., Kim D.C., Jacobs J.E.: Ventricular diverticula on cardiac CT: more common than previously thought. *AJR*, 2007, 189: 204-208.
6. Bashour T.T., Saalouke M., Yazji Z.I.: Apical left ventricular diverticulum with Ebstein malformation. *Am Heart J*, 1988, 115: 1332-1334.
7. Maron B.J., Hauser R.G., Roberts W.C.: Hypertrophic cardiomyopathy with left ventricular apical diverticulum. *Am J Cardiol*, 1996, 77: 1263-1265.
8. Cantrell J.R., Haller J.A., Ravitch M.M.: A syndrome of congenital defects involving the abdominal wall, sternum, diaphragm, pericardium, and heart. *Surg Gynecol Obstet*, 1958, 107: 602-614.
9. Mady C.: Left ventricular diverticulum: analysis of two operated cases and review of the literature. *Angiology*, 1982, 33: 280-286.
10. Marijon E., Ou P., Fermont L., et al.: Diagnosis and outcome in congenital ventricular diverticulum and aneurysm. *J Thorac Cardiovasc Surg*, 2006, 131: 433-437.
11. Brachlow A., Sable C., Smith S., Slack M., Martin G.: Fetal diagnosis and postnatal follow-up of an asymptomatic congenital left ventricular diverticulum. *Pediatr Cardiol*, 2002, 23: 658-660.
12. Ohlow M.A.: Congenital left ventricular aneurysms and diverticula: definition, pathophysiology, clinical relevance and treatment. *Cardiology*, 2006, 106: 63-72.
13. Wu J.M., Yu C.Y.: Isolated congenital left ventricular diverticulum. *Pediatric Cardiol*, 1996; 17: 254-256.
14. Pitol R., Cardoso C.O., Cardoso C.R., et al.: Congenital ventricular diverticulum associated with ventricular tachycardia. *Arq Bras Cardiol*, 2005, 84: 173-175.
15. Handler C.E., Walker J.M.: Congenital diverticulum of the left ventricle presenting as heart failure and diagnosed by magnetic resonance imaging. *Int J Cardiol*, 1989, 22: 115-119.
16. Bernasconi A., Deleziode A.L., Menez F., Vuillard E.: Prenatal rupture of a left ventricular diverticulum: A case report and review of the literature. *Prenat Diagn*, 2004, 24: 504-507.
17. Bell W.E., Ehmke D.A.: Diverticulum of the left ventricle in a child with fatal cerebral embolization. *South Med J*, 1971, 64: 537-540.
18. Tandar A., Meredith K.G., Anderson J.L.: Multiple left ventricular diverticuli in an asymptomatic adult: Case report and review of the literature. *Catheter Cardiovasc Interv*, 2007, 69: 453-458.
19. Parthenakis F.I., Kochiadakis G.E., Patrianakos A.P., Hamilos M.I.: Peripheral arterial embolism due to a left ventricular diverticulum in a young adult. *Chest*, 2005, 127: 1452-1454.
20. Archbold R.A., Robinson N.M., Mills P.G.: Long-term follow-up of a true contractile left ventricular diverticulum. *Am J Cardiol*, 1999, 83: 810-813.