

MALIGNANT TRANSFORMATION OF AN ABDOMINAL INFLAMMATORY MYOFIBROBLASTIC TUMOR WITH DISTANT METASTASES IN A CHILD

C.W. Ernst¹, J. Van Der Werff Ten Bosch¹, B. Desprechins², J. de Mey², M. De Maeseneer²

Inflammatory myofibroblastic tumors (IMT) are lesions that mostly affect young adults and children. The tumor is made up of myofibroblasts and a mixed inflammatory infiltrate and rarely undergoes malignant transformation. We present a case of a 13-year-old boy with a pelvic mass diagnosed as IMT which underwent malignant transformation and metastasised to the liver. We report the ultrasound, computed tomography (CT) and magnetic resonance (MR) findings of this rare disorder.

Key-word: Neoplasms, in infants and children.

Inflammatory myofibroblastic tumor (IMT) was initially described as a pulmonary lesion in young adults. It has subsequently been found in various anatomic locations and over a wide age range (1). IMT is a distinctive tumor of proliferating myofibroblasts with a background of an inflammatory infiltrate. The tumor rarely undergoes malignant transformation. The potential for recurrence and focal invasion are reported in oncologic, surgical, and radiological literature (2-4). Reports and radiologic imaging of malignant transformation, however, are very few (5) and to our knowledge, this is the first report that provides imaging of distant metastasis. The purpose of this article is to raise awareness of this possibly aggressive entity.

Case report

A 13-year-old boy presented with a 5-week history of abdominal pain, weight loss, and anorexia. On physical examination the child appeared skinny and pale. On palpation a 10-cm large suprapubic mass was evident. Medical history of the patient was positive for neurofibromatosis type 1. Hence, initially the mass was thought to represent a neurofibroma.

Ultrasound showed a solid, heterogeneous multilobulated pelvic mass (Fig. 1), which measured 12 x 9.5 x 7 cm. Right hydronephrosis was also evident.

On CT the mass showed mild contrast enhancement. Hydronephrosis of the right kidney and the presence of a liver nodule were also demonstrated.

MRI of the liver showed a well-demarcated lesion in the antero-superior segment of the right liver lobe with marked contrast uptake (Fig. 2). Pelvic MRI showed a large, mildly enhancing, pelvic mass (11.3 x 8.2 x 7.6 cm) with compression of the bladder (Fig. 3). A Positron Emission Tomography scan (PET) was performed and showed marked uptake of labelled glucose in the lesion suggesting a malignant origin. No hypermetabolic foci were seen in the liver.

The patient underwent exploratory laparotomy. Pathologic examination of the specimen showed a variable cellular spindle cell neoplasm with a vascular myxoid pattern and a prominent inflammatory background. Multiple histiocytoid cells with vesicular nuclei were present. The tumor cells were plump with high mitotic activity.

Due to the prominent subpopulation of histiocytoid cells and the high mitotic activity the tumor was diagnosed as an IMT with malignant transformation.

No efficient treatment regimen has been reported for this type of malignancy. Several case reports suggest different combinations of chemotherapy with variable results. A first attempt was made with a course of chemotherapy: fosfamide, vincristin, and actinomycin, with no results. One month after diagnosis the patient underwent surgery. The pelvic mass and liver lesion were removed. Pathology of the liver lesion confirmed the diagnosis of a metastasis. Following surgery the patient was given one cycle of doxorubicin and cisplatin and one

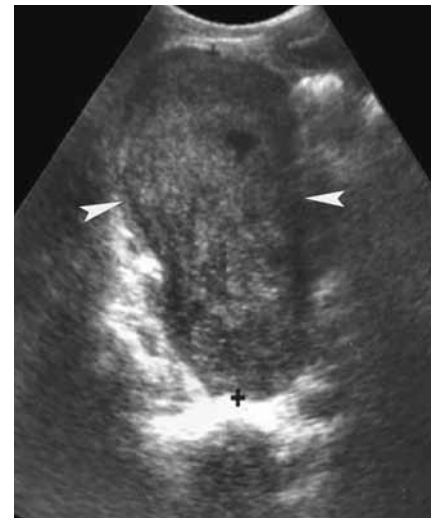

Fig. 1. — Ultrasound of the abdomen showing a large pelvic mass, predominantly solid with a few small hypoechoic areas (arrows).

month later he received two cycles of high dose methotrexate (HD-MTX) with a one week interval. Nevertheless a tumor recurrence was found 8 weeks postoperatively. Follow up CT showed a new pelvic mass (10 x 8.2 x 7 cm) and two lesions in the liver (6.1 x 5.9 x 5.5 cm, 3.7 x 4.9 x 3 cm). The patient underwent a resection of the pelvic mass. Intraoperatively, severe peritoneal seeding and invasion of the intestinal mucosa (rectum and sigmoid) was noted. Subtotal resection of the tumor (approximately 90%) was achieved with resection of the invaded part of the recto-sigmoid. The liver lesions were not resected. The patient received another 2 cycles of doxorubicin, cisplatin, and high dose methotrexate. Interval CT scan after those two cycles of chemotherapy showed a significant enlargement of the liver lesions (10.8 x 9.2 x 9.9 cm, 10.2 x 8 x 9.5 cm) with almost total invasion of the liver, important subcapsular expansion

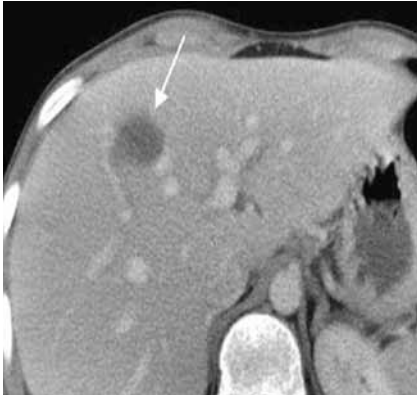


Fig. 2. — Abdominal CT demonstrates the presence of a hypodense non-enhancing liver lesion of 1.5 cm (arrow).

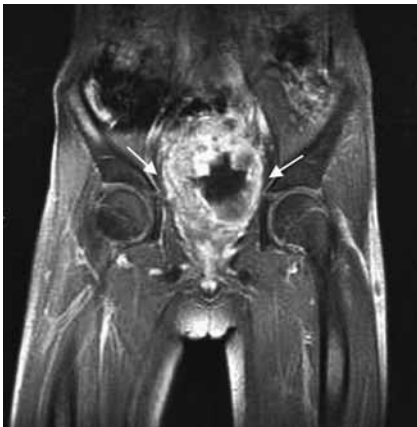

Fig. 3. — Coronal post-gadolinium T1-weighted fat sat image shows a large irregularly enhancing, centrally located pelvic mass (arrows).

and the presence of two new intraperitoneal masses (5.4 x 5.7 x 5.1 cm, 5.3 x 5.2 x 5.7 cm) (Fig. 4) The disease was progressive and chemotherapy was unsuccessful. The patient was given palliative care.

Discussion

Inflammatory myofibroblastic tumor (IMT) is a distinct tumor of proliferating myofibroblasts with an associated inflammatory infiltrate. The tumor rarely undergoes malignant transformation (1). IMTs most often are seen in the lungs of young adults, but there have been reports in children, and in various anatomic locations (6-8). Extrapulmonary IMTs in children have been described involving the mesentery (1, 9), retroperitoneum, abdominal soft tissues, liver (10), bladder (11, 12), mediasti-

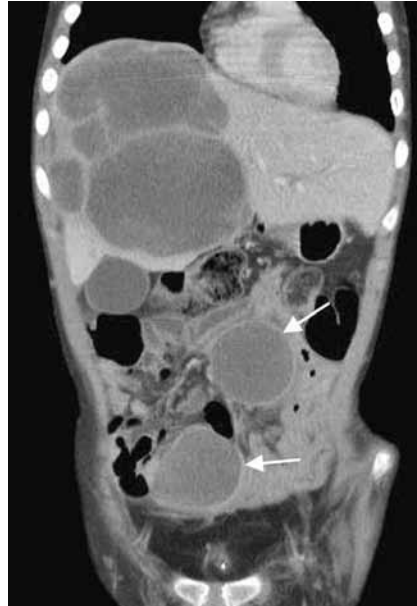


Fig. 4. — Interval computed tomography during second chemotherapy shows a significant enlargement of the liver lesions and the presence of two similar intra-peritoneal lesions (arrows).

num, head and neck, extremities, appendix (7), and kidneys (1, 13) with the largest tumors occurring in the abdomen and retroperitoneum (1, 14).

The clinical presentation of IMT varies depending on the site where the tumor originates. Symptoms of intra-abdominal IMT include the presence of a mass, fever, pain, and weight loss.

The etiologic factors responsible for development of IMT are not clearly understood. Although some investigators still believe it is a benign neoplasm, IMT is now more regarded as a true neoplasm with a wide spectrum of biologic behaviour, varying from the more frequent benign lesions to the uncommon tumors that are multifocal and prone to multiple recurrences (1, 10, 15). This latter subset of tumors may show local invasion or even metastasise (1, 2, 16). Due to the rarity of these tumors, very little is described in the medical literature regarding the management of aggressive IMTs. One positive outcome of abdominal IMT with malignant transformation (without distant metastasis) has been reported. This successful outcome was related to cisplatinum, doxorubicin, and methotrexate as an adjunct to surgical resection (1). No reports were found of a successful treatment of

IMT with malignant transformation and distant metastasis (or multifocal lesions).

The radiologic features of intra-abdominal IMTs are non-specific. Abdominal radiographs may show displacement of bowel segments caused by soft tissue mass and possible amorphous calcification within the tumor (6, 17). Ultrasound and CT show a solid, sometimes heterogeneous, well demarcated mass (6, 17). These imaging modalities may show infiltrative or multifocal disease. The MR findings are similar to the CT findings. Conventional barium studies can further characterize intestinal involvement (2, 9).

The differential diagnosis based on imaging includes soft tissue sarcoma (rhabdomyosarcoma), lymphoma and neuroblastoma. The precise diagnosis of IMT can be made pathologically. Awareness and inclusion of IMT in the differential diagnosis of aggressive abdominal processes may have important treatment implications (2).

IMT should be viewed as a tumor of low malignant potential. Rarely it shows local recurrence and metastatic spread (1).

In summary, we report a case of a IMT that was locally aggressive in addition to showing metastatic spread.

References

1. Dishop M.K., Warner B.W., Dehner L.P., et al.: Successful treatment of inflammatory myofibroblastic tumor with malignant transformation by surgical resection and chemotherapy. *J Pediatr Hematol/Oncol*, 2003, 25: 153-158.
2. Hedlund G.L., Navoy J.F., Galliani C.A., et al.: Aggressive manifestations of inflammatory pulmonary pseudotumor in children. *Pediatr Radiol*, 1999, 29: 112-116.
3. Chan J.K.C.: Inflammatory pseudotumor: A family of lesions of diverse nature and etiologies. *Adv Anat Pathol*, 1996, 3: 156-171.
4. Bahadori M, Liebow AA: Plasma cell granulomas of the lung. *Cancer*, 1973, 191-208.
5. Meis J.M., Enzinger F.M.: Inflammatory fibrosarcoma of the mesentery and retroperitoneum: a tumor closely simulating inflammatory pseudotumor. *Onkologie*, 2001, 24: 368-372.
6. Karnak I., Senocak M.E., Ciftci A.O., et al.: Inflammatory myofibroblastic tumor in children: Diagnosis and treatment. *J Pediatr Surg*, 2001, 36: 908-912.
7. Bonnet J.P., Basset T., Dijoux D.: Abdominal inflammatory myofibroblastic tumors in children: report of an

- appendical case and review of the literature. *J Pediatr Surg*, 1996, 31: 1311-1314.
8. Pettinato G., Manivel J.C., De Rosa N., et al.: Inflammatory myofibroblastic tumor (plasma cell granuloma). *Am J Clin Pathol*, 1990, 94: 538-546.
 9. Day D.L., Sane S., Dehner L.P.: Inflammatory pseudotumor of the mesentery and small intestine. *Pediatr Radiol*, 1986, 16: 210-215.
 9. Coffin C.M., Humphrey P.A., Dehner L.P.: Extrapulmonary inflammatory myofibroblastic tumor: A clinical and pathologic survey. *Semin Diagn Pathol*, 1998, 15: 85-101.
 10. Albores-Saavedra J., Manivel J.C., Essendorf H., et al.: Pseudosarcomatous myofibroblastic proliferations in the urinary bladder of children. *Cancer*, 1990, 66: 1234-1241.
 11. Hojo H., Newton W.A., Hamoudi A.B., et al.: Pseudosarcomatous myofibroblastic tumor of the urinary bladder in children: a study of 11 cases with review of the literature. An intergroup rhabdomyosarcoma study. *Am J Surg Pathol*, 1995, 19: 1224-1236.
 12. Williams M.E., Longmaid H.E., Trey G., et al.: Renal failure resulting from infiltration by inflammatory myofibroblastic tumor responsive to corticosteroid therapy. *Am J Kidney Dis*, 1998, 31: E5.
 13. Coffin C.M., Watterson J., Priest J.R., et al.: Extrapulmonary inflammatory myofibroblastic tumor (inflammatory pseudotumor). A clinicopathologic and immunohistochemical study of 84 cases. *Am J Surg Pathol*, 1995, 19: 859-872.
 14. Conte M., Milanaccio C., Nantron M., et al.: Multiple inflammatory fibrosarcoma of the abdominal cavity in a child. *Med Pediatr Oncol*, 1996, 27: 198-201.
 15. Scott L., Blair G., Taylor G., et al.: Inflammatory pseudotumor in children. *J Pediatr Surg*, 1988, 23: 755-758.
 16. Kim K.A., Park C.M., Lee J.H., et al.: Inflammatory myofibroblastic tumor of the stomach with peritoneal dissemination in a young adult: imaging findings in a case report. *Abdom Imag*, 2003 Oct 28 (Epub ahead of print).
-