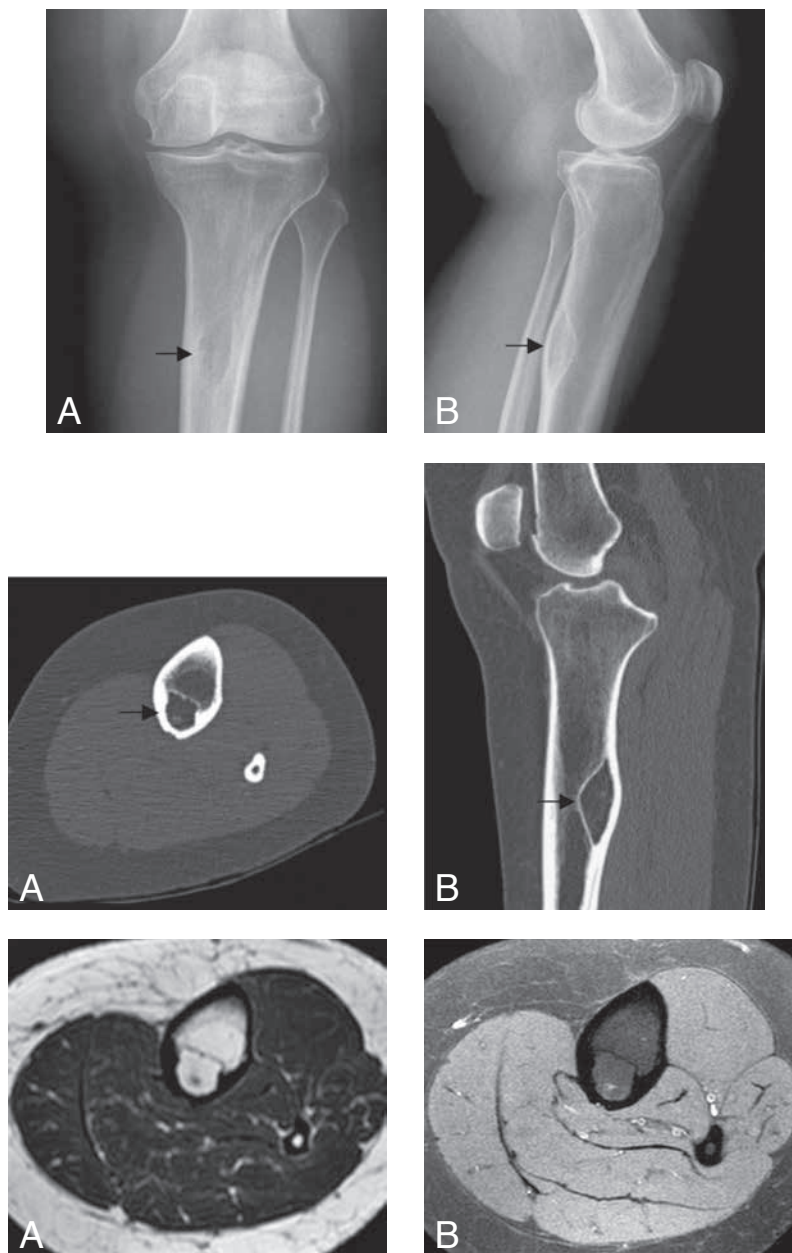


## INTRACORTICAL LIPOMA OF THE TIBIA

G.C. Bloemsma, M.J. van Kints<sup>1</sup>

**Key-word:** Lipoma and lipomatosis

**Background:** A 42-year-old female presented with chronic knee pain. Anamnesis and physical examination revealed no history of traumatic events. Furthermore, there was no local tenderness, swelling or warm aspect of the knees or tibiae. On conventional imaging, gonarthrosis was seen, as well as a well-defined diaphyseal osteolytic lesion. Further evaluation of the bone lesion was done by CT scan and MRI.



	1A	1B
Fig.	2A	2B
	3A	3B

## Work-up

Conventional radiograph of the left tibia (Fig. 1) shows on anterior-posterior view (A) a well-defined diaphyseal osteolytic lesion with sclerotic margins (arrow). Lateral view (B) reveals expansion of this lesion to the dorsal portion of the cortex but without periosteal reaction (arrow).

Unenhanced CT scan of the left tibia (Fig. 2) includes an axial section (A) and a reformatted image in the sagittal plane (B). Both images show an intracortical located osteolytic lesion with attenuation values of approximately -60 HU (arrow). The lesion shows one small central hyperdense focus.

On MRI of the left tibia (Fig. 3), axial T1-weighted TSE-image (A), the lesion has a high signal intensity, equal to that of surrounding bone marrow and subcutaneous fat. The lesion is sharply demarcated. A small hypointense spot is detected centrally within the lesion. No bone marrow abnormality or periosteal reaction are apparent. On axial Gd-enhanced T1-weighted SPIR-image (B), the lesion appears homogeneous with intermediate signal intensity and contains a small central spot with high signal intensity.

## Radiological diagnosis

Based on the typical radiological findings the diagnosis of *an intracortical lipoma of the tibia* was made.

## Discussion

Intraosseous lipomas are very rare benign bone tumors. To the best of our knowledge only one tibial intracortical intraosseous lipoma has ever been described in the English literature before.

Intraosseous lipomas are typically found during the fourth and fifth decades and are of intramedullary metaphyseal origin. Common sites include the femur, tibia, fibula, calcaneus and vertebral bodies. Multifocality has been described.

Most intraosseous lipomas are asymptomatic, and are detected incidentally on conventional radiographs. When symptomatic, symptoms usually

consist of aching, mild pain and swelling at the affected site.

The pathogenesis of intraosseous lipoma remains controversial. Hypotheses include a true benign fatty tumor and secondary development following infarction or trauma. Histologically, intraosseous lipomas can be divided in three stages: Stage 1 consists of solid tumors of viable adipocytes. Stage 2 consists of transitional lesions with partial fat necrosis and focal calcifications in addition to areas of viable adipocytes. Stage 3 consists of devitalized fat and varying degrees of cyst formation, calcification and new bone formation.

In the presented case, gonarthrosis explains the chronic knee pain, and the osteolytic lesion was an incidental finding. After conventional radiographic imaging, however, the radiological differential diagnosis is extensive, including fibrous dysplasia, enchondroma, bone infarct, osteoblastoma, simple bone cyst and chondrosarcoma.

Both the fat-attenuation of the lesion on CT scan, and the signal characteristics on MRI (hyperintensity on T1-weighted images, hypointensity on T1-weighted SPIR-imaging), revealing the fatty content, led to the diagnosis of intraosseous (intracortical) lipoma with central calcification.

For asymptomatic intraosseous lipomas there is no indication for treatment. Nonetheless, especially when a lesion becomes symptomatic, follow-up is recommended because malignant transformation has been described.

## Bibliography

1. Lee S.J., Yoon J.H., Bae J.I., et al.: Intracortical lipoma of the femur. *Skelet Radiol*, 2007, 36: 77-81.
2. Milgram J.V.: Malignant transformation in bone lipomas. *Skelet Radiol*, 1990, 19: 347-352.
3. Resnick D.: Tumors of fatty differentiation. In: *Diagnosis of bone and joint disorders*. 3rd ed. Philadelphia, Pa: Saunders, 1995, Chapter 83: 3811-3815.
4. Unni K.K.: Lipoma and liposarcoma. In: *Unni K.K., Dahlin's Bone Tumors: General aspects and data on 11087 cases*. Philadelphia: Lippincott-Raven, 1996, 349-353.