

RETAINED SURGICAL SPONGE

P. Dewachter¹, N. Van De Winkel², F. Vandembroucke¹, J. de Mey¹

Key-word: Foreign bodies, in air and food passages

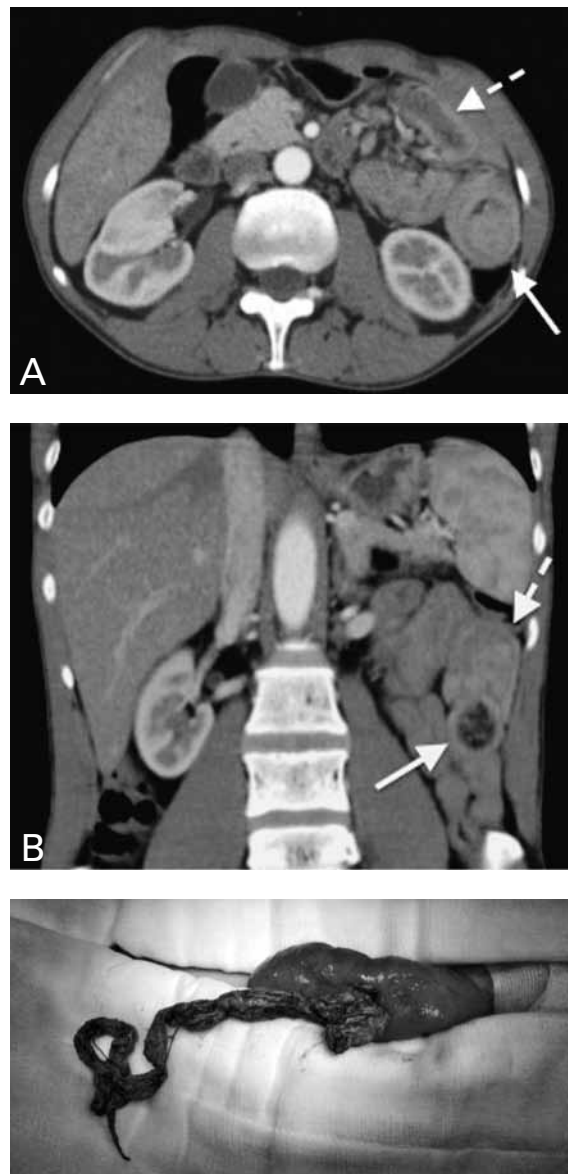
Background: A 36-year-old male presented to the emergency department with a 4-day history of vomiting, loss of appetite and gastric pain radiating to the back. He denied fever and diarrhea. His medical record includes a Billroth-II procedure in another hospital for gastric lymphoma in 1992, hepatitis C and ferripriva anemia.

Vital signs in the emergency department were normal.

The abdomen was soft and diffusely tender. There was voluntary guarding in response to palpation and decreased bowel sounds on auscultation.

There was no palpable mass. Further clinical examination was normal.

The WBC count was 6800 Mc/L, CRP 14.7 mg/L and LDH 2516 U/L.



Work-up

Contrast-enhanced CT scan of the abdomen (Fig. 1) shows on axial image at the level of the mid-abdomen (A) a target-like lesion in the jejunum demonstrating intussusception in the left hemiabdomen (arrow) and an intestinal loop with thickened wall and inhomogeneous content (dashed arrow). Coronal reformatted image (B) shows a localized area with thickening of the bowel wall and intraluminal area of mixed, predominantly low density (arrow) and confirms the segment with intussusception (dashed arrow). Photograph of the surgical specimen (Fig. 2) confirms the radiological findings.

Radiological diagnosis

Based on the imaging appearance, the diagnosis of jejunal intussusception with a *bezoar* was made and was confirmed by explorative surgery. Surprisingly a surgical sponge from the previous surgery 18 years ago was found.

Discussion

Intussusception is the invagination or telescoping of a proximal segment of bowel (intussusceptum) into the lumen of a distal segment (intussusciens).

Intussusception is common in children: only 5% of all cases occur in adults. Intussusception accounts for 1 to 5% of intestinal obstructions in adults.

Symptoms in adults are less specific than in children: the classical triad of abdominal pain, abdominal mass, blood per rectum is absent. Mostly, clinical examination suggests intestinal obstruction. Most adult intussusceptions are short segment, transient and non-obstructing. They are not associated with a lead tumor mass, although there is a higher risk for malignancy. Most commonly surgical intervention is needed.

Gossypibomas (gossypium: Latin for cotton and boma: Swahili for "place of concealment") are cotton sponges accidentally retained in the body postoperatively. It is also called retained surgical sponge (RSS).

Literature reported an incidence ranging from 1/18 760 to 1/5 027. RSS can remain asymptomatic

for many years and is mostly detected incidentally by radiologic investigations. Since cotton sponges are inert, they don't stimulate specific biochemical reactions apart from adhesions and granuloma formation.

Symptoms are often present shortly after surgery, and consist of nonspecific abdominal pain and intestinal obstruction. Surgical sponges may completely migrate into the intestinal lumen without any apparent opening in the intestinal wall. This penetration is caused by an inflammatory process generated in the intestinal wall evolving to necrosis and favored by peristaltic movements. Various imaging techniques are used to diagnose RSS. If the sponge has a radiopaque marker, the diagnosis can be made easily by an abdominal x-ray. On ultrasound a well-defined mass featuring a wavy hyperechoic area and a dense acoustic shadow is seen. On CT these lesions appear as well-bordered masses that contain hyperdense material and show capsular enhancement. Calcification of the wall of the mass may be observed. MRI usually shows a well-defined mass with a fibrous capsule that exhibits low signal intensity on T1-weighted images and high signal intensity on T2-weighted images.

Treatment of RSS includes removal of the material via US-guided, laparoscopic or open surgical exploration of the abdomen and treatment of complications.

Bibliography

1. Gawande A.A., Studdert D.M., Orav E.J., et al.: Risk factors for retained instruments and sponges after surgery. *N Engl J Med*, 2003, 348: 229-235.
2. Puri S.K., Panicker H., Narang P., et al.: Spontaneous transmural migration of a retained surgical sponge into the intestinal lumen – a rare cause of Intestinal obstruction. *Indian J Radiol Imaging*, 2002, 12: 137-139.
3. Silva C.S., Caetano M.R., Silva E.A., et al.: Complete migration of retained surgical sponge into ileum without sign of open intestinal wall. *Arch Gynecol Obstet*, 2001, 265: 103-104.
4. Yildirim S., Tarim A., Nursal T.Z., et al.: Retained surgical sponge (gossypiboma) after intraabdominal or retroperitoneal surgery: 14 cases treated at a single center. *Langenbecks Arch Surg*, 2006, 391: 390-395.