

## CONSERVATIVE SURGERY FOR LEFT-SIDED ISOLATED TUBAL TORSION IN PREGNANCY

A. ten Cate<sup>1</sup>, S. Han<sup>1</sup>, A.-S. Vliegen<sup>2</sup>, L. Lewi<sup>1</sup>, J. Verhaeghe<sup>1</sup>, F. Claus<sup>2</sup>

**We report a case of severe lower abdominal pain in a pregnant woman at 35 weeks and 4 days of gestation. Early diagnosis of an isolated left-sided tubal torsion was established by ultrasound and emergency magnetic resonance imaging (MRI). Subsequent detorsion surgery was able to prevent the need for salpingectomy. The role of emergency imaging and conservative surgery in isolated tubal torsion is discussed.**

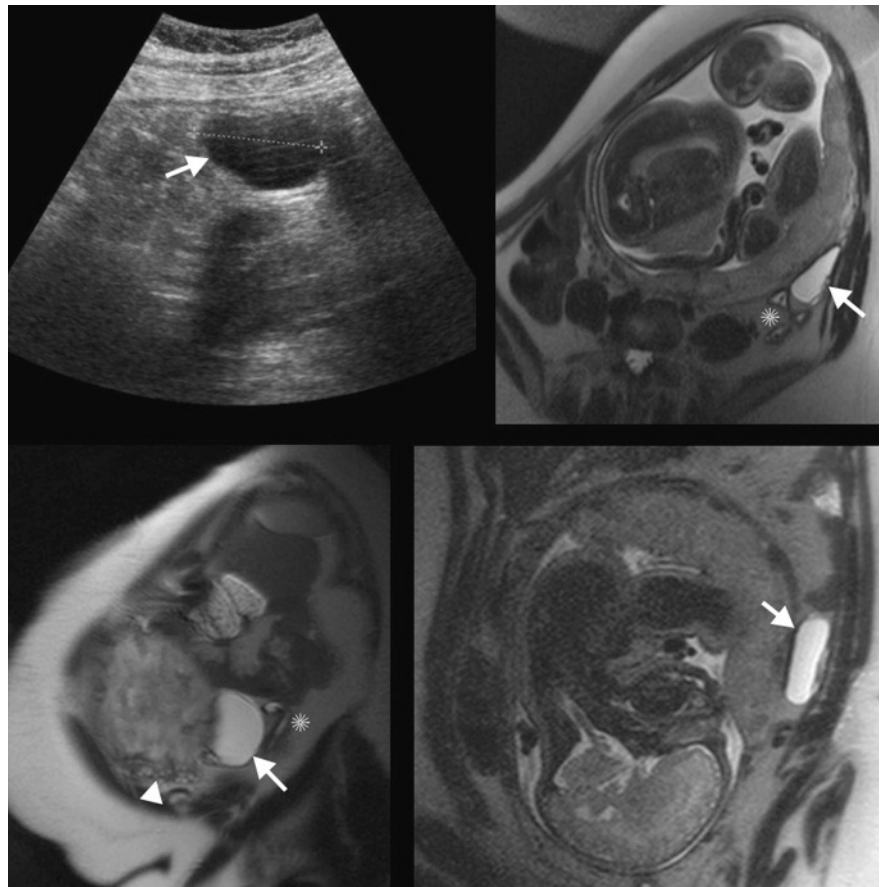
**Key-word:** Fallopian tubes, torsion.

### Case report

A 33-year-old patient with an uneventful medical history presented with severe pain in the lower left quadrant of the abdomen at a gestational age of 35 weeks and 4 days. The onset of the pain was sudden and paracetamol was ineffective as pain relief. A few days earlier the patient had experienced a similar pain which had resolved spontaneously. Aside from vomiting, no other complaints were mentioned. There were no signs of obstetric complications.

On clinical examination there was a localized tenderness and rebound sign in the lower left quadrant. All biochemical results, including a complete blood count, CRP and urine analysis, were within normal range. Ultrasound examination showed a cystic lesion of 4.4 centimeter situated on the left side lateral of the uterus. MRI was performed for further characterization of the cystic lesion. T2-weighted images showed a segmental dilation of the distal left tuba in proximity of the normal-appearing ipsilateral ovary and sigmoid colon (Fig. 1). No signs of hemorrhage were detected on the T1-weighted images. The radiologic diagnosis of an isolated fallopian tubal torsion or torsion of a (para)tubal cyst was suggested.

Labor was induced with vaginal application of Dinoprost. After 12 hours a cesarean section was performed because of persistent pain, unresponsive to tramadol, in absence of cervical dilatation. A healthy boy was born. Subsequent inspection of the abdomen showed an edematous and purple left fallopian tube. A threefold torsion



*Fig. 1.* — Transabdominal sonographic image (upper left) and T2-weighted magnetic resonance images (clockwise starting from upper right: axial, coronal and sagittal view) of the segmental dilation (white arrow) of the distal left tuba. Note the close proximity of the normal-appearing sigmoid colon (asterix) and ipsilateral ovary (arrowhead).

around its long axis was observed. The tubal fimbriae were also purple and enlarged (Fig. 2A). The contralateral tuba as well as both ovaries appeared normal; no paratubal cysts were present. A normal position of the fallopian tube was reestablished

via detorsion and prompt revascularization occurred (Fig. 2B). The postoperative recovery was uneventful and no further pain occurred.

### Discussion

Isolated tubal torsion is a rare cause of lower abdominal pain, affecting women in their reproductive age. The incidence in non-pregnant women is estimated at one in 1.5 million (1). In pregnancy, only nineteen cases of isolated fallopian

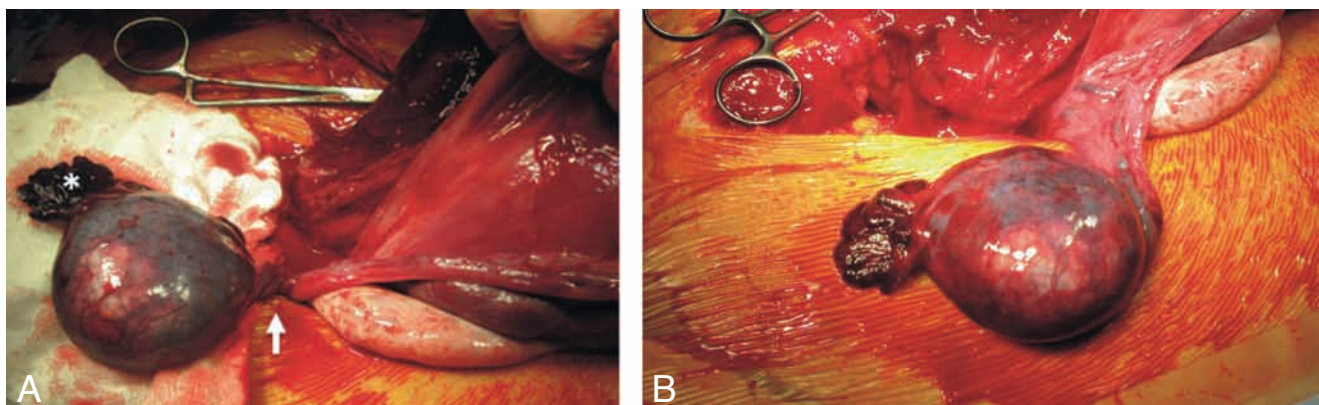


Fig. 2. — A: At laparotomy, inspection of the abdomen showed an edematous and purple left fallopian tube. A three-fold torsion around its long axis was seen (white arrow). The tubal fimbriae were also purple and enlarged (asterisk). B: A normal position of the fallopian tube was reestablished and prompt revascularization occurred.

tubal torsion have been described in the literature (1). Several risk factors for tubal torsion have been proposed, such as anatomical abnormalities (e.g. adhesions, previous pelvic surgery, neoplasms, hydro- or pyosalpinx or paratubal cysts), physical conditions (abnormal tubal or intestinal peristalsis, muscular spasms or enlarged hyperstimulated ovaries), hemodynamic abnormalities (venous congestion) and trauma (2, 3). Pregnancy increases the risk of tubal torsion, especially in advanced gestational age, due to changed anatomical position of the uterus and adjacent adnexa (1, 4).

The clinical presentation of a tubal torsion is abdominal lower quadrant pain, with or without radiation to the flank. Nausea, vomiting, dysuria and mild vaginal bleeding can be associated. Laboratory results are often normal in the early stage, but leucocytosis, fever and peritonitis may be present in cases complicated by necrosis (3). Ninety percent of the cases published in literature are right-sided tubal torsion, which is hypothesized to be due to the presence of the sigmoid on the left side of the uterus.

Diagnosis is difficult due to the nonspecific clinical presentation and normal laboratory findings at early

stages (3). Sonographic findings are the presence of a cystic lesion, adjacent to a normal ovary, both morphologically and on Doppler flow. In case ultrasound is non-diagnostic, MRI is the imaging modality of choice for further work-up of abdominopelvic pathology in pregnant women (5). By combining an excellent soft tissue contrast with a large field of view, MRI allows to further differentiate cystic lesions and examine their relationship with intestinal and internal genital structures. The combination of pre-operative imaging by ultrasound and MRI can successfully diagnose a tubal torsion (6).

Surgical intervention is necessary for detorsion of the fallopian tube. Early diagnosis and timely surgical intervention can prevent irreversible damage to the fallopian tube and may thereby prevent salpingectomy (4). To our knowledge this is the first pregnant case reported in the literature for which conservative surgery was performed. Detorsion of the fallopian tube by laparoscopy should be considered until a gestational age of 32-34 weeks. In more advanced gestational age the preferred method of intervention is laparotomy, which allows immediate delivery of the fetus by cesarean

section. In absence of necrosis of the fallopian tube, fetal and maternal outcome are good.

#### References

1. Origoni M., Cavoretto P., Conti E., Ferrari A.: Isolated tubal torsion in pregnancy. *Eur J Obstet Gynecol Reprod Biol*, 2009, 146: 116-120.
2. Comerci G., Colombo F.M., Stefanetti M., Grazia G.: Isolated fallopian tube torsion: a rare but important event for women of reproductive age. *Fertil Steril*, 2008, 90: 1198-1115.
3. Krissi H., Shalev J., Bar-Hava I., Langer R., Herman A., Kaplan B. Fallopian tube torsion: laparoscopic evaluation and treatment of a rare gynecological entity. *J Am Board Fam Pract*, 2001, 14: 274-277.
4. Orazi C., Inserra A., Lucchetti M.C., Schingo P.M.: Isolated tubal torsion: a rare cause of pelvic pain at menarche. Sonographic and MR findings. *Pediatr Radiol*, 2006, 36: 1316-1318.
5. Wieseler K.M., Bhargava P., Kanal K.M., Vaidya S., Stewart B.K., Dighe M.K.: Imaging in pregnant patients: examination appropriateness. *Radiographics*, 2010, 30: 1215-1229.
6. Park B.K., Kim C.K., Kim B.: Isolated tubal torsion: specific signs on pre-operative computed tomography and magnetic resonance imaging. *Acta Radiol*, 2008, 49: 233-235.