

MANAGING CORONARY ARTERY VEIN BYPASS GRAFT STUMP PSEUDO-ANEURYSM: A NOVEL APPROACH

V. Rachapalli, R. Evans, D. Roberts¹

We present a case of a pseudoaneurysm of the saphenous vein graft stump, which was managed with percutaneous thrombin injection. Aneurysms of a saphenous vein coronary bypass graft are rare and aneurysms of a bypass graft stump are even rarer. To our knowledge this is the first reported case of a pseudoaneurysm of a graft stump with the use of thrombin to treat a saphenous vein graft pseudoaneurysm.

Key-word: Aneurysm, coronary.

Case report

An 85-year-old man, with a background cardiac history of myocardial infarction and aortic stenosis, presented with a shortness of breath and central chest pain, radiating to the right arm and back. A coronary angiogram demonstrated a narrowing of the proximal right coronary artery (RCA), mid left anterior descending artery (LAD) and proximal first diagonal (D1) branch. He underwent an aortic valve replacement and three vessel bypass. The left internal mammary artery was anastomosed to the LAD, venous grafts (VG) to the D1 and RCA. He underwent emergency sternotomy 10 days later, for pericardial tamponade, which demonstrated bleeding from two sites: a slit in the VG to the D1 which was 2 cm from the aortic end and from the lateral angle of the aortotomy. The VG slit was thought to be secondary to trauma from the emergency bedside sternotomy. Post-operatively patient developed respiratory compromise, renal impairment and a sternal wound infection. Eight days later, he became hypotensive, with oozing from the sternal wound. A further sternotomy identified the source of bleeding to be from the previous site of injury to the VG. It was elected to resect the VG, as repairing it would have severely compromised the luminal diameter.

Further sternal bleeding occurred 25 days after the third operation, but was haemodynamically stable. A computer tomography (CT) of the chest demonstrated a pseudoaneurysm from the aortic stump of the VG to D1 (Fig. 1A,B). Under CT guidance a spinal needle was inserted into the pseudoaneurysm sac parasternally. 1.2 mls of thrombin

was injected (Fig. 2A). Post procedure CT scan showed that the pseudoaneurysm had thrombosed

(Fig. 2B). Ten days after the thrombin injection, the patient developed further bleeding from the sternal wound. CT of the chest demonstrated that the pseudoaneurysm had recurred. A repeat thrombin injection was undertaken. A spinal needle was placed into the sac of the pseudo-

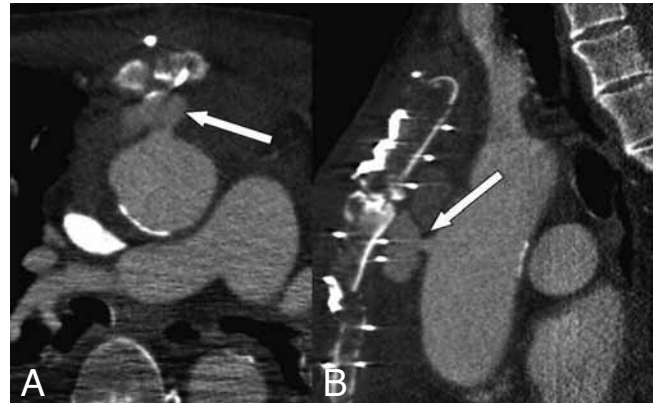


Fig. 1. — Pseudoaneurysm in the anterior mediastinum lying anterior to the ascending aorta (A, arrow). The graft stump (arrow) is seen in relation to the pseudoaneurysm on the sagittal reformats (B).

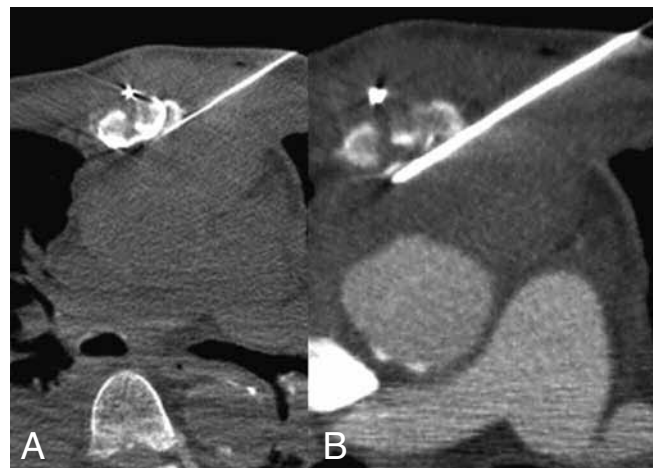


Fig. 2. — Panel A demonstrates the spinal needle with its tip placed in the position of the pseudoaneurysmal sac. Panel B shows occlusion of the pseudoaneurysm on the post contrast scan.

From: Department of Radiology, Morriston Hospital, Swansea, UK.
Address for correspondence: Dr V. Rachapalli, FRCR., 8 Ffordd Ty Unnos, Cardiff CF14 4NJ, UK.

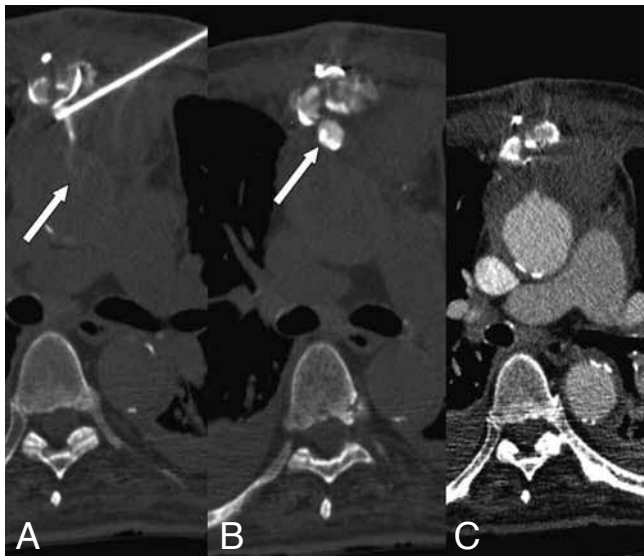


Fig. 3. — A demonstrates the tip of the needle in the pseudoaneurysm. Upon contrast injection through the needle, contrast is seen to enter the aorta (arrow) and pseudoaneurysmal sac (B, arrow). Post contrast CT after thrombin injection demonstrates occlusion of the pseudoaneurysmal sac (C).

aneurysm and contrast injected via the spinal needle demonstrating the recurrent pseudoaneurysm and patency of the graft stump (Fig. 3A,B). 1.5 ml of thrombin was injected, with the immediate post procedure CT showing complete thrombosis of the pseudoaneurysm (Fig. 3C). The patient had an uneventful recovery and a repeat CT prior to discharge showed no recurrence of the pseudoaneurysm.

Discussion

Aneurysmal dilatation of a coronary bypass graft is a rare. True aneurysms are more common and involve the mid portion of the graft. Pseudoaneurysms tend to occur at anastomotic sites (1). The first case of an aneurysm of a saphenous vein coronary bypass graft (SVCBG) was reported in 1972 and of a pseudoaneurysm in 1975 by Riahi et al. (2, 3). Trauma to the vein at the time of harvest, inherent areas of weakness (valve site and branch points), atherosclerotic degeneration of the vessel wall and wall necrosis are some of the possible explanations for their formation (4). Infection at

insertion site and wound dehiscence also play a contributory role (1). Most aneurysms are detected incidentally. They can present as myocardial ischaemia or infarction, fistula formation into the cardiac chambers and rupture (5).

Graft stump aneurysms which arise, from the proximal aspect of the graft (1 to 2 cm length extending from the aortic attachment left after a redo surgery) are rare (6). Given the increased risk of rupture and associated morbidity and mortality, surgical management is recommended; especially if it is a pseudoaneurysm (1). To date there has been only one other report of an aneurysm related to a stump of a previously ligated SVCBG. This was proven histologically to be a true aneurysm and was managed surgically (6). But an endovascular approach could be considered particularly if the patient is not medically fit to undergo surgery. Tamirisa et al successfully managed a patient with a pseudoaneurysm of the internal mammary artery graft by local thrombin injection (7). In the current case the original pseudoaneurysm probably recurred due to the high arterial

pressure which exists in the ascending thoracic aorta. We would suggest that these patients are kept under review and at the earliest sign of a bleed be re-imaged. To the best of our knowledge, this is the first case where a pseudoaneurysm was associated with a coronary artery bypass graft stump and CT guided percutaneous thrombin has been successfully used to treat this complication.

Conclusion

Though pseudoaneurysms of a SVCBG are rare, their presence requires urgent treatment as the potential for rupture is high. Though surgery is the mainstay of treatment; endovascular therapy can be a viable option, particularly if the patient is not suitable for surgery. This case demonstrates that CT guided percutaneous thrombin injection can be further option for successful treatment.

References

1. Memon A.O., Huang R.I., Marcus F., Xavier L., Alpert J.: Saphenous vein graft aneurysm: case report and review. *Cardiol Rev*, 2003, 11: 26-34.
2. Carrasquilla C., Weaver A.W.: Aneurysm of a saphenous vein graft to the common carotid artery. *Vasc Surg*, 1972, 6: 66-69.
3. Riahi M., Vasu C.M., Tomatis L.A., Schlosser R.J., Zimmerman G.: Aneurysm of a saphenous vein bypass graft to coronary artery. *J Thorac Cardiovasc Surg*, 1975, 70: 358-364.
4. Benchimol A., Harris C.L., Desser K.B.: Aneurysms of an aorto-coronary artery saphenous vein bypass graft—a case report. *Vasc Surg*, 1975, 9: 261-264.
5. Trop I., Samson L., Cordeau MP., Leblanc P., Therasse E.: Anterior mediastinal mass in a patient with prior saphenous vein coronary artery bypass grafting. *Chest*, 1999, 115: 572-576.
6. Baldwin RT., Klima T., Frazier OH., Lonquist J., Radovancevic B.: True aneurysm of the saphenous vein graft stump associated with CABG in a cardiac transplant patient. *Ann Thorac Surg*, 1992, 54: 978-979.
7. Tamirisa PK., Rinder M., Singh J., Lonquist J., Radovancevic B.: Thrombin injection to treat pseudoaneurysm of internal mammary artery bypass graft: a case report. *Catheter Cardiovasc Interv*, 2002, 57: 548-551.