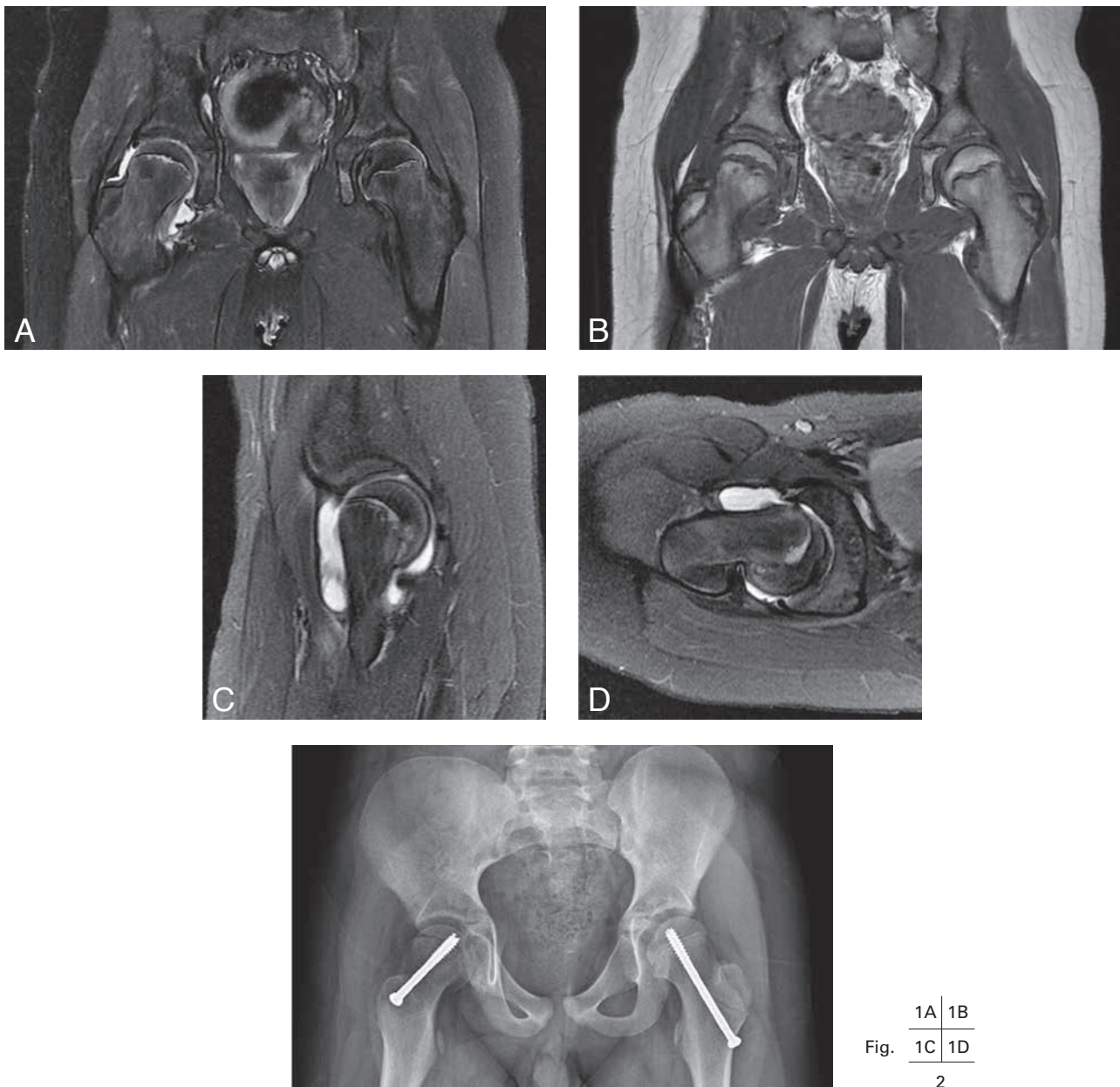


## SLIPPED CAPITAL FEMORAL EPIPHYSIS

L. Topff, G. Gelin, M. Grieten<sup>1</sup>

**Key-word:** Hip, abnormalities

**Background:** A 10-year-old boy presented with a 4-week history of limping gait and right knee pain. The patient did not have a fever. Physical examination revealed limited range of motion of the right hip. Standard laboratory inflammatory parameters were normal. Plain radiographs of the knee and hip taken in another hospital didn't show abnormalities. Because of persistent diagnostic uncertainty, MRI of the hips was performed. Patient was treated surgically.



## Work-up

MRI of the hips (Fig. 1), shows on coronal proton density fat saturated image (A) a joint effusion in the right hip. The line of Klein (line drawn up the lateral edge of the femoral neck) does not intersect the lateral part of the femoral epiphysis on the right hip. Furthermore, the right femoral epiphysis appears smaller. Coronal T1-weighted image (B) demonstrates widening of the physal plate of the right hip. On sagittal (C) and axial (D) proton density fat sat image of the right hip, posterior and medial displacement of the femoral head are noticed. Intra-articular effusion is present. There is disruption of the physis and some bone marrow edema is observed adjacent to the physis. Metaphyseal impingement on the anterior rim of the acetabulum can also be seen.

Anteroposterior radiograph of the pelvis with both hips (postoperative image) (Fig. 2) shows screw fixation of the right hip and prophylactic fixation of the contralateral hip.

## Radiological diagnosis

Based on the MRI findings the diagnosis of *slipped capital femoral epiphysis* was evident. Treatment consisted of surgical fixation of the epiphysis with a central screw and prophylactic fixation of the contralateral hip.

## Discussion

Slipped capital femoral epiphysis (SCFE) is the most common adolescent hip abnormality. SCFE is a relatively non traumatic fracture through the physis of the proximal femur and can be regarded as a Salter-Harris type I injury. Clinically patients present with hip and/or knee pain and a limp.

The etiology of SCFE is multifactorial including biomechanical and biochemical factors. SCFE is strongly associated with obesity. Hormonal changes in the adolescent may also contribute. SCFE is more common in boys than girls with an average age of onset at 12 years.

The diagnosis of SCFE is traditionally made with anteroposterior and true or frog-leg lateral radiographs. Bilateral slips are frequent so both hips should be visualised. Initial imaging demonstrates physal widening on the affected side. The femoral epiphysis will slip posteriorly and may appear smaller. Medial displacement of the femoral head will be apparent when slippage continues.

There is no role for advanced imaging in established cases of SCFE. However, when diagnostic uncertainty persists such as in the above-mentioned case, additional cross sectional imaging can be performed. MRI can accurately document detailed features of slips and can demonstrate very early changes when radiographs or CT appear normal (the so-called pre-slip). Synovitis, intra-articular effusion and bone marrow edema are apparent on T2-weighted images. T1-weighted images demonstrate physal widening. MRI can also assess the vascular viability of the femoral head.

Differential diagnosis of SCFE includes traumatic fractures, Legg-Calve-Perthes disease, septic arthritis, osteomyelitis and stress fractures.

The natural history of untreated SCFE is associated with the risk of a more advanced degree of slippage and later degenerative joint disease. Early complications of SCFE include avascular necrosis and chondrolysis. Therefore, early diagnosis and prompt treatment are crucial for long-term function of the hip joint. The treatment of SCFE generally consists of surgical stabilisation with in situ fixation of the epiphysis using a pin or screw. Prophylactic fixation of the contralateral hip is often performed.

## Bibliography

1. Boles C.A., el-Khoury G.Y.: Slipped capital femoral epiphysis. *Radiographics*, 1997, 17: 809-823.
2. Gholve P.A., Cameron D.B., Millis M.B.: Slipped capital femoral epiphysis update. *Curr Opin Pediatr*, 2009, 21: 39-45.
3. Tins B., Cassar-Pullicino V., McCall I.: The role of pre-treatment MRI in established cases of slipped capital femoral epiphysis. *Eur J Radiol*, 2009, 70: 570-578.