

## CORRECTION

# Correction: Imaging Findings of the Distal Radio-Ulnar Joint in Trauma

M. Mespreuve<sup>\*†</sup>, F. Vanhoenacker<sup>\*†‡</sup> and K. Verstraete<sup>†</sup>

This article details a correction to: Mespreuve, M, Vanhoenacker, F and Verstraete, K 2015 Imaging Findings of the Distal Radio-Ulnar Joint in Trauma. *Journal of the Belgian Society of Radiology*, 99(1), pp. 1-20, DOI: <http://dx.doi.org/10.5334/jbr-btr.846>

**Keywords:** Wrist; injuries

### Correction

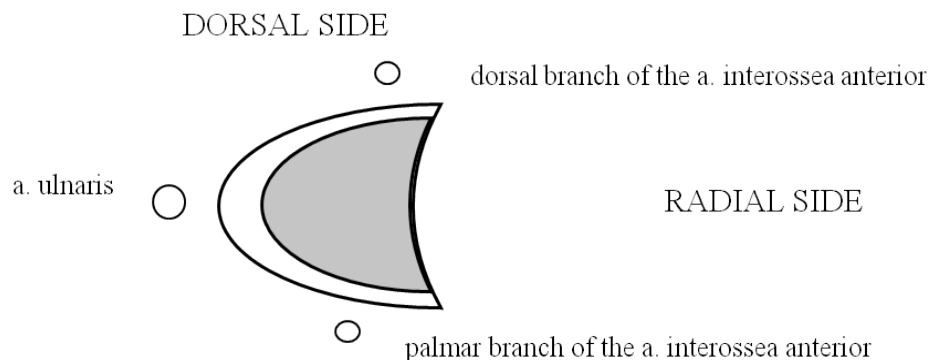
- Fig. 2** on page 3: part of the caption (from C-D) should be replaced by:
  - 'C. The meniscus homologue (thick arrow) is interposed between the ulnar styloid and disc proximally and the cartilage of the triquetral bone distally.
  - D. The volar and dorsal part of the RUL (vertical arrows) are fixed between the radial notch and the base of the ulnar styloid. The m. extensor carpi ulnaris lies within his sulcus (horizontal arrow).
  - E. The m. extensor carpi ulnaris lies on the ulnar styloid (horizontal arrow). The central disc (TFC)

(vertical arrows) is attached at the radial side to the cartilage of the radial sigmoid notch and at the ulnar side to the styloid.'

- Fig. 27** on page 14: the grey zone in the center of the figure 27 fails. Correct figure infra (as in the galley proof).

### References

- Mespreuve, M, Vanhoenacker, F, and Verstraete, K.** Imaging Findings of the Distal Radio-Ulnar Joint in Trauma. *Journal of the Belgian Society of Radiology*. 2015; 99(1): 1-20. DOI: <http://doi.org/10.5334/jbr-btr.846>.



**Figure 27:** The correct image.

\* St.-Maarten General Hospital, Leopoldstraat 2, 2800 Mechelen, Belgium  
marc.mespreuve@skynet.be

† University Hospital Ghent, Belgium  
filip.vanhoenacker@telenet.be; koenraad.verstraete@UGent.be

‡ University Hospital Antwerp, Belgium

**How to cite this article:** Mespreuve, M, Vanhoenacker, F and Verstraete, K 2015 Correction: Imaging Findings of the Distal Radio-Ulnar Joint in Trauma. *Journal of the Belgian Society of Radiology*, 99(1), pp.129-130, DOI: <http://dx.doi.org/10.5334/jbr-btr.966>

**Published:** 02 December 2015

**Copyright:** © 2015 The Author(s). This is an open-access article distributed under the terms of the Creative Commons Attribution 3.0 Unported License (CC-BY 3.0), which permits unrestricted use, distribution, and reproduction in any medium, provided the original author and source are credited. See <http://creativecommons.org/licenses/by/3.0/>.



*Journal of the Belgian Society of Radiology* is a peer-reviewed open access journal published by Ubiquity Press.

**OPEN ACCESS**