

IMAGES IN CLINICAL RADIOLOGY

## Perforation from Ingested Wooden Toothpick: A Colon Diverticulitis Mimicker

Key learning point: Foreign bodies should be considered in the differential when imaging displays bowel inflammation

François Dermesropian, Olivier Dewit and Vassiliki Pasoglou

**Keywords:** colic perforation; toothpick; diverticulitis mimicker

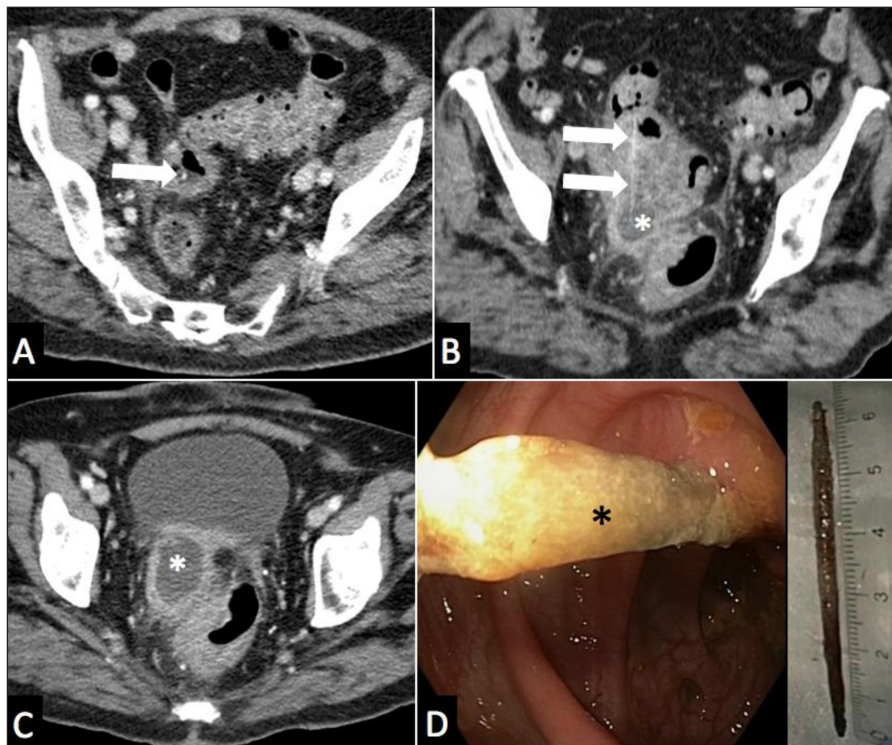
### Case

A 79-year-old woman presented to the emergency room with a month history of intermittent hypogastric abdominal pain and fever. Past medical history included diabetes and diverticular colic disease. CT scan with intravenous contrast medium (**Figure 1A, B, C**) demonstrated a colic diverticulosis with sigmoid wall thickening, extra-digestive abscess of 4.5 cm in diameter (white asterisk), adjacent fat stranding and a 60 mm long, 2 mm thick high density linear structure (arrow) coursing through the colic wall and the abscess. Covered colic

perforation and an extra-digestive abscess related to a wooden toothpick were suspected. After antibiotherapy, recto-sigmoidoscopy (**Figure 1D**) was able to confirm and retrieve the wooden toothpick (black asterisk) embedded through the colic wall. Clinical follow-up was favorable.

### Comment

Perforation can occur in any part of the gastro-intestinal tract as the toothpick can migrate in various anatomic structures. Adequate therapy depends on the localization



**Figure 1.**

of the toothpick and the complications. Endoscopic removal is used as the first-line approach. Surgery is reserved for failed endoscopic retrieval and complicated cases such as fecal peritonitis, fistulas, migration to extra-digestive structures and bleeding [1]. This case highlights the fact that tiny or lowly attenuating foreign bodies should be considered in presence of bowel inflammation on imaging, as this may have paramount implication for management.

### Competing Interests

The authors have no competing interests to declare.

### Reference

1. **Sarici, IS, Topuz, O, Sevim, Y**, et al. Endoscopic Management of Colonic Perforation due to Ingestion of a Wooden Toothpick. *Am J Case Rep.* 2017 Jan; 20(18): 72–75. DOI: <https://doi.org/10.12659/AJCR.902004>

**How to cite this article:** Dermesropian, F, Dewit, O and Pasoglou, V. Perforation from Ingested Wooden Toothpick: A Colon Diverticulitis Mimicker. *Journal of the Belgian Society of Radiology.* 2019; 103(1): 51, 1–2. DOI: <https://doi.org/10.5334/jbsr.1885>

**Submitted:** 15 July 2019

**Accepted:** 30 August 2019

**Published:** 12 September 2019

**Copyright:** © 2019 The Author(s). This is an open-access article distributed under the terms of the Creative Commons Attribution 4.0 International License (CC-BY 4.0), which permits unrestricted use, distribution, and reproduction in any medium, provided the original author and source are credited. See <http://creativecommons.org/licenses/by/4.0/>.



*Journal of the Belgian Society of Radiology* is a peer-reviewed open access journal published by Ubiquity Press.

OPEN ACCESS 