

## MULTIPLE MYELOMA INVOLVING THE CRICOID CARTILAGE

B. Floré<sup>1</sup>, R. Hermans<sup>1</sup>

**We present the case of a man with dyspnea due to a mass in the cricoid cartilage that turns out to be an extramedullary plasmacytoma. Although the patient has a history of multiple myeloma, the disease only rarely affects the cricoid cartilage. Other subglottic lesions possibly involving the cricoid cartilage are squamous cell carcinoma, chondroma, chondrosarcoma and metastasis. The imaging characteristics suggesting extramedullary plasmacytoma arising from the cricoid consist of thinning and expansion of the cartilage laminae without mucosal lesions nor soft tissue mass adjacent to the cricoid cartilage. The patient was successfully treated with radiation therapy and peroral steroids.**

**Key-word: Plasmacytoma.**

### Case report

A 73 year old man with a history of multiple myeloma and pulmonary embolism presents at the emergency department with progressive dyspnea. A CT-angiography of the pulmonary arteries showed no pulmonary embolism or other relevant thoracic disease.

The next two weeks dyspnea increased and wheezing arose. Hence the man was examined by the otorhinolaryngologist. A laryngoscopy demonstrated a subglottic stenosis with an estimated lumen diameter of 50%. Subsequently, a CT study of the neck was done which showed a bulging mass arising from the cricoid cartilage resulting in a significant subglottic stenosis (Fig. 1 A, B (white arrows)). The mass is horseshoe-shaped with a free anterior border and a cranial-caudal length of 2 cm. The mass has a slightly hyperdense solid consistence with shell-like calcifications in its periphery. There is no aggressive growth in the adjacent structures. No lymphadenopathies were seen in the examined region.

Additionally, a number of osteolytic bone lesions are visible in vertebral bodies (Fig. 1C (white arrows)), in the right clavicle (Fig. 1A, black arrow) and in the sternal bone (Fig. 1C (white arrow)).

As the patient was known with multiple myeloma, treated by chemotherapy from 2009 till 2011, a cricoid localisation of multiple myeloma was hypothesized.

Given that a differentiation between a cricoid location of multiple myeloma versus primary subglottic

malignancy invading the cricoid cartilage was necessary for adequate therapy, a tracheoscopy with needle biopsy of the mass was performed. Histopathology and cytology showed groups of plasma cells consistent with multiple myeloma.

Treatment consisted of radiotherapy and peroral steroids.

A follow-up CT study 6 months after therapy, showed a considerable volume decrease of the mass lesion (Fig. 2, white arrows), with decrease of the subglottic stenosis. The patients' dyspnea and wheezing vanished.

### Discussion

A subglottic mass in elder males leads to a rather broad differential diagnosis (1). First of all, a squamous cell carcinoma should be considered. If the lesion seems to originate from a laryngeal cartilage structure, a chondrosarcoma or chondroma is at the top of the diagnostic list. With a history of multiple myeloma, an extramedullary plasmacytoma affecting the cricoid cartilage should also be included within this list. All mentioned pathologies occur mostly in older male patients.

The most common origin of a subglottic mass narrowing the airway lumen is squamous cell carcinoma. Especially in older males with chronic tobacco and alcohol use, it is the most likely diagnosis. Cricoid cartilage alterations include lysis and sclerosis. Contrary to our case, this may be accompanied by infiltration of the glottic and extralaryngeal soft tissues.

Non-squamous cell malignancies of the larynx, hypopharynx and cervical esophagus are extremely rare. These include sarcomas, lymphoma and malignant minor salivary gland tumors. Squamous and non-squamous cell malignancies invade the cricoid cartilage secondary.

The mass in this patient appeared to involve only the cricoid. Thus a cartilaginous tumor, namely a chondrosarcoma or chondroma, should be considered. These typically present as an expansile mass within the cartilage with intact mucosal surfaces, containing arc or ring-like calcifications. Laryngeal chondroma or chondrosarcoma cannot be distinguished based on their imaging features. Most chondrosarcoma are low grade with good prognosis, however outcome worsens in patients with myxoid or dedifferentiated chondrosarcoma.

Metastatic disease in the larynx by distant malignancies is very rare (2). Most frequently the primary tumor in these cases is cutaneous melanoma or renal carcinoma. Sporadic cases originating from lung and colon adenocarcinoma have also been documented. Contrary to squamous cell carcinoma, metastatic disease tends to leave the mucosa intact.

This patient was known with multiple myeloma. Therefore an extramedullary plasmacytoma (EMP) involving the thyroid cartilage should also be considered. EMP of the cricoid cartilage is a very rare entity with less than 10 cases described in literature (3, 4). After osseous metaplasia with formation of a central marrow space, plasmacytoma may originate within the cricoid marrow, or disseminated plasma cells may be seeded and grow in the marrow space.

Multiple myeloma is next to non-Hodgkin lymphoma the most common hematological malignancy

*From:* 1. Department of Radiology, University Hospitals Leuven, Leuven, Belgium.  
*Address for correspondence:* Prof Dr R. Hermans, M.D., Herestraat 49, B-3000 Leuven, Belgium. E-mail: Robert.Hermans@uzleuven.be

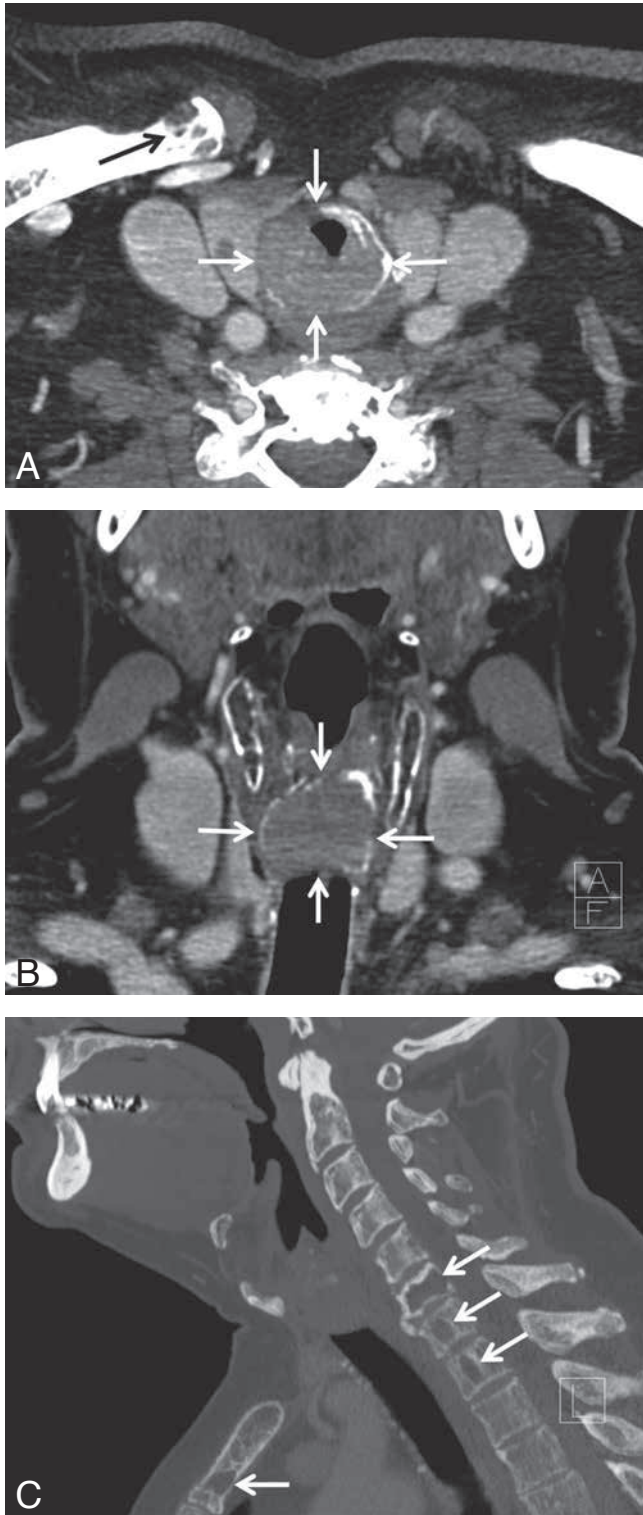


Fig. 1. — A: White arrows show bulging mass in cricoid cartilage resulting in a significant subglottic stenosis. Black arrow shows osteolytic bone lesion in right clavicle. B: White arrows show bulging mass originating from the cricoid resulting in a significant subglottic stenosis. The cricoid is still bordered by a thin, calcified layer. C: The white arrows on this sagittal reformatting in bone window show multiple osteolytic bone lesions in different vertebrae and the manubrium sterni.

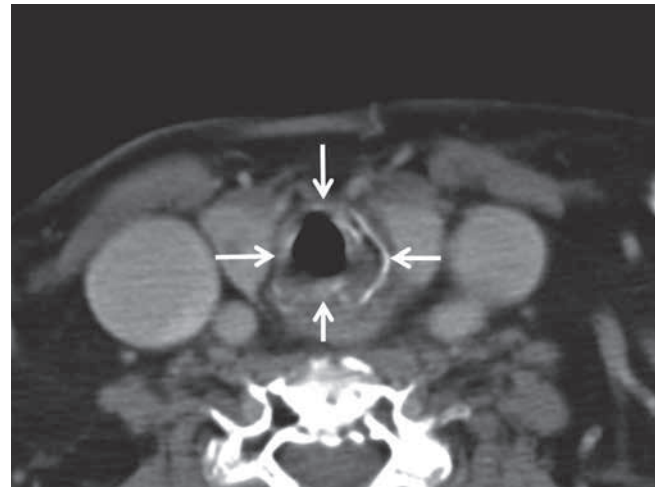


Fig. 2. — Follow-up CT study 6 months after treatment. The white arrows show a considerable volume decrease of the mass, with decrease of the subglottic stenosis.

(10%). Incidence rates are higher in men and increase with age, in particular between age 65 and 70. When there is involvement of cricoid cartilage by multiple myeloma, the mucosa of the subglottic regions usually remain intact, without evidence of tumor extension into the airway. The thinning and expansion of the cartilage laminae, and the lack of a soft tissue mass adjacent to the thyroid cartilage, suggest that the mass originated within the cricoid itself.

Radiation therapy is a standard local treatment for multiple myeloma (4), as done in this case. The effects of radiation therapy are cumulative to systemic therapy with steroids, chemotherapy or bone marrow transplantation.

## References

1. Hermans R. (ed.): Head and Neck Cancer Imaging, 2nd ed. Springer-Verlag, 2012, pp. 58-91.
2. Nicolai P., et al.: Metastatic Neoplasms to the Larynx: Report of Three Cases. *The Laryngoscope*, 1996, 106: 851-855.
3. Straetmans J., Stokroos R.: Extramedullary plasmacytomas in the head and neck region. *Eur Arch Otorhinolaryngol*, 2008, 265: 1417-1423.
4. Shimada T., et al.: Multiple myeloma involving the thyroid cartilage. *Auris Nasus Larynx*, 2007, 34: 277-279.