

A GIANT RETROPERITONEAL LIPOMA PRESENTING AS A SCIATIC HERNIA: MRI FINDINGS

S. Duran¹, M. Cavusoglu¹, E. Elverici¹, T.D. Unal²

Sciatic hernia is a rare condition and its clinical diagnosis is uneasy. Herniation of pelvic organs as well as of retroperitoneal neoplasm has been reported in the literature. Sciatica occurs as a result of compression of the sciatic nerve by the herniated sac. We present a case of retroperitoneal lipoma in a patient who had lower leg complaint and describe the imaging findings.

Key-word: Nerves, sciatic.

Sciatic hernia is a rare pelvic floor hernia that occurs through the greater or lesser sciatic foramen. It is generally determined by the symptoms related to herniated content such as bowel obstruction, pelvic pain, and ureteric obstruction. Sciatic hernias may present as a rare cause of sciatica (1-4). Retroperitoneal neoplasm with sciatic hernia is considered the rarest, with a very limited number of published reports in the literature. The lesions are deeply located and clinical diagnosis is uneasy. In this respect, imaging modalities are needed for both identification of the lesion content and assessment of the sciatic nerve. We present a case of retroperitoneal lipoma which was diagnosed through the lower leg symptoms, along with the magnetic resonance imaging (MRI) findings.

Case report

A 39-year-old woman was admitted to our hospital with a five-month long pain in the left leg and difficulty in walking. Clinical history revealed that she has been suffering from pain spreading from the left hip/sciatic to the leg/limb for one year. She had no history of trauma, systemic disease or drug use. Physical examination did not reveal dorsiflexion in the ankle or toe of the left foot. Laboratory findings were normal. On lumbar MRI, disc herniation pressing on the nerve root was not observed. However, as a presacral hyperintense mass was observed on T2 weighted sagittal sections, lower abdominal MRI was performed. MRI demonstrated a large intra- and extra-pelvic fatty mass traversing the greater sciatic foramen. The diameter of the lesion was 6 x 13 x 15 cm.

This mass was well-circumscribed, isointense with the subcutaneous fatty tissue (Fig. 1A, B) and did not show contrast enhancement after intravenous contrast agent administration (Fig. 1C). The mass displaced adjacent anatomic structures, for example the rectum was displaced to the right. No atrophy was observed in gluteal muscles. Pathology following the surgery established the diagnosis of osteolipoma with mature osteoid tissue regions and mature lipocytes (Fig. 2).

Discussion

Sciatic hernia is a rare pelvic floor herniation. It was first reported by Papan in 1750 (1). It is more common in adults and women (2, 3). Sciatic hernia may present as a gluteal mass or with complications of the pelvis content (2-4). This content may be small intestine (obstruction), ureter and bladder (infection and obstruction), ovaries and fallopian tubes (pelvic pain), colon, omentum and Meckel's diverticulum (1). Sciatica occurs as a result of compression of the sciatic nerve by the herniated sac (1-5). To our knowledge, four well-documented descriptions of a lipoma herniating through the sciatic foramen have been reported, and it was first defined in 1964 (3, 4, 6, 7). In our case, retroperitoneal lipoma which showed sciatic herniation and made nerve compression was determined during the examination for the lower leg.

Lipomas are mesenchymal soft tissue neoplasms which consist of mature fatty cells. They are commonly observed in adults. They usually present as painless soft-tissue masses, although larger ones can be

painful when they compress peripheral nerves (5). Clinical diagnosis is uneasy due to the gluteal muscle covering any mass protruding through the sciatic foramen (4). Diagnosis is made possible by imaging modalities. Fat has a characteristic appearance on cross-sectional imaging methods. Magnetic resonance signal characteristics of a fat containing neoplasm allows a reliable diagnosis by detecting signal intensity areas within the mass equal to that of subcutaneous fat on all the pulse sequences, with loss of signal on fat-suppression techniques. On T1- and T2 weighted images, there may be thin fibrous septae with low signal intensity whereas the lesions that do not typically show contrast enhancement (8, 9).

Pathology of lipomatous lesions with sciatic herniation from the retroperitoneal region has been reported as well-differentiated liposarcoma (atypical lipoma) which is different from our case (3, 4, 7). While liposarcoma is the common primary neoplasm in the retroperitoneal region, lipoma is rare in this region (7). MRI is helpful in distinguishing these two entities. Kransdorf et al defined significant features to help distinguish lipoma from liposarcoma in their study, the most important one being the presence of thickened septa, nodular and/or globular areas of non-adipose tissue within the lesion, associated non-adipose masses, and a total amount of non-adipose tissue composing more than 25% of the lesion (8). Ohguri et al. reported that thick septa, nodular or lobular/patchy non-adipose components in retroperitoneal and deeply located well-differentiated liposarcomas were more common than the subcutaneous lesions (10).

Preoperative diagnosis of these deep lipomatous lesions is important for treatment planning (5). MRI is the modality of choice to evaluate the sciatic nerve in cases of sciatic hernia (2). Surgical treatment of the

From: 1. Clinic of Radiology, 2. Clinic of Pathology, Ankara Numune Education and Research Hospital, Ankara, Turkey.

Address for correspondence: Dr Semra Duran, M.D., Clinic of Radiology, Ankara Numune Education and Research Hospital, Ankara Numune Eğitim ve Araştırma Hastanesi, Talatpaşa Bulvarı No: 5, Altındağ-Ankara 06100, Turkey.
E-mail: Semraduran91@gmail.com

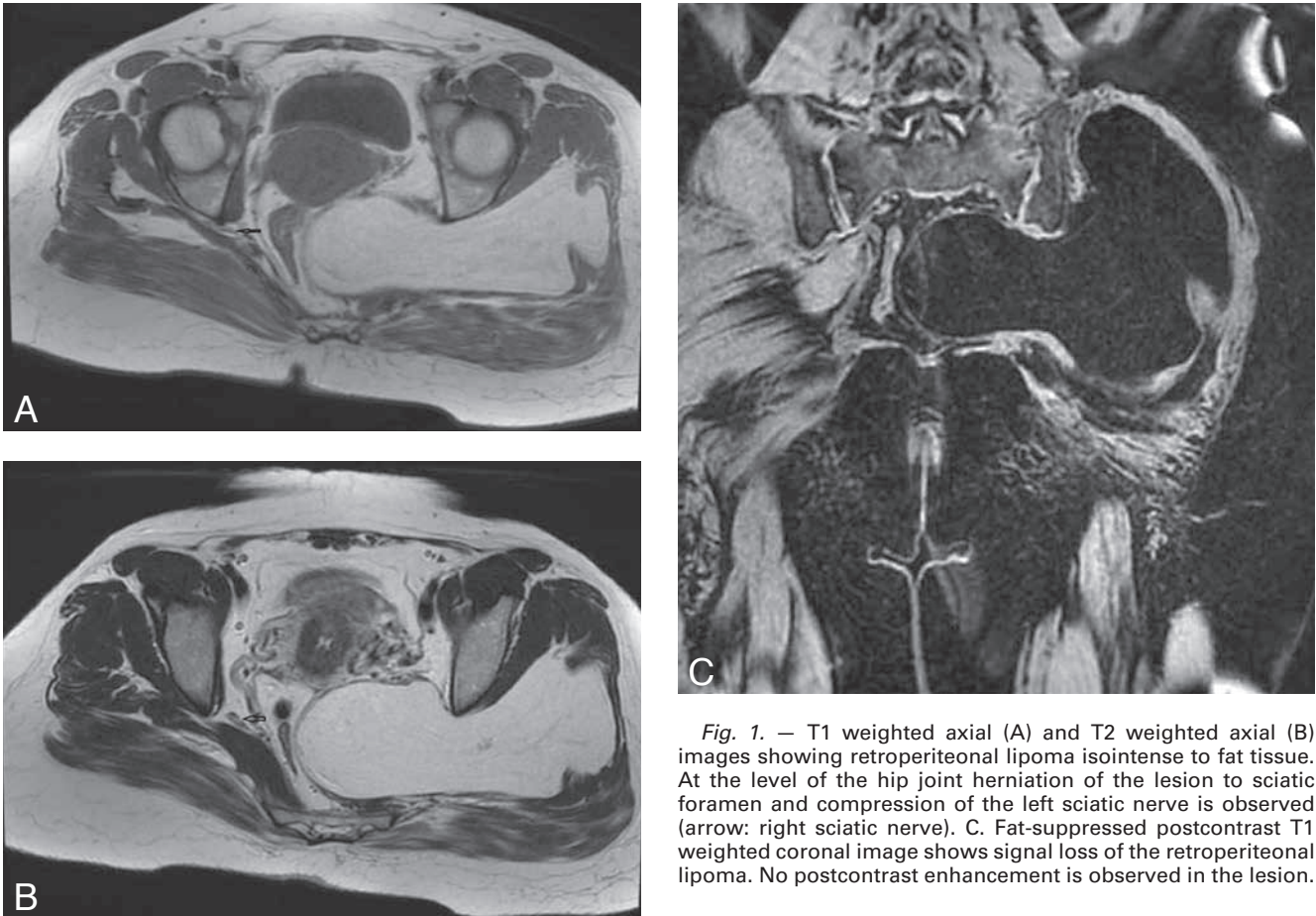


Fig. 1. — T1 weighted axial (A) and T2 weighted axial (B) images showing retroperitoneal lipoma isointense to fat tissue. At the level of the hip joint herniation of the lesion to sciatic foramen and compression of the left sciatic nerve is observed (arrow: right sciatic nerve). C. Fat-suppressed postcontrast T1 weighted coronal image shows signal loss of the retroperitoneal lipoma. No postcontrast enhancement is observed in the lesion.

symptomatic sciatic hernia is possible with transabdominal or transgluteal approach (3).

In conclusion, sciatic hernia is a rare entity and MRI enables a precise diagnosis of the tumor and the adjacent anatomical structures.

References

1. Losanoff J.E., Basson M.D., Gruber S.A., Weaver D.W. Sciatic hernia: A comprehensive review of the world literature (1900-2008). *Am J Surg*, 2010, 199: 52-59.
2. Chitranjan S.R., Kandpal H., Madhusudhan K.S.: Sciatic hernia causing sciatica: MRI and MR neurography showing entrapment of sciatic nerve. *Br J Radiol*, 2010, 83 (987): e65-6.
3. Skipworth R.J., Smith G.H., Stewart K.J., Anderson D.N. The tip of the iceberg: A giant pelvic atypical lipoma presenting as a sciatic hernia. *World J Surg Oncol*, 2006, 4: 33
4. Cappellani A., Zanghi A., Di Vita M., et al.: Very atypical presentation of a retroperitoneal "atypical lipoma". *Ann Ital Chir.*, 2007, 78: 69-72.
5. López-Tomassetti Fernández E.M., Hernández J.R., Esparragon J.C., García A.T., Jorge V.N.: Intermuscular lipoma of the gluteus muscles compressing the sciatic nerve: An inverted sciatic hernia. *J Neurosurg*, 2012, 117: 795-799.
6. Kerry R.L., Tygart R.L., Glas W.W.: Lipoma: a "reversed" perineal sciatic hernia. *Am J Surg*, 1964, 107: 883-884.
7. Hansch A., Gajda M., Boettcher J., Pfeil A., Kaiser W.A.: Incomplete paresis of the sciatic nerve due to massive atypical lipoma of the pelvis: A case report. *Cases Journal*, 2008, 1: 296.
8. Kransdorf M.J., Bancroft L.W., Peterson J.J., et al.: Imaging of the fatty tumors: Distinction of lipoma and well-differentiated liposarcoma. *Radiology*, 2002, 224: 99-104.
9. Galant J., Marti-Bonmati L., Saez F., et al.: The value of fat-suppressed T2 or STIR sequences in distinguishing lipoma from well-differentiated liposarcoma. *Eur Radiol*, 2003, 13: 337-343.
10. Ohguri T., Aoki T., Hisaoka M., et al.: Differential diagnosis of benign peripheral lipoma from well-differentiated liposarcoma on MR imaging: Is comparison of margins and internal characteristic useful? *AJR*, 2003, 180: 1689-1694.

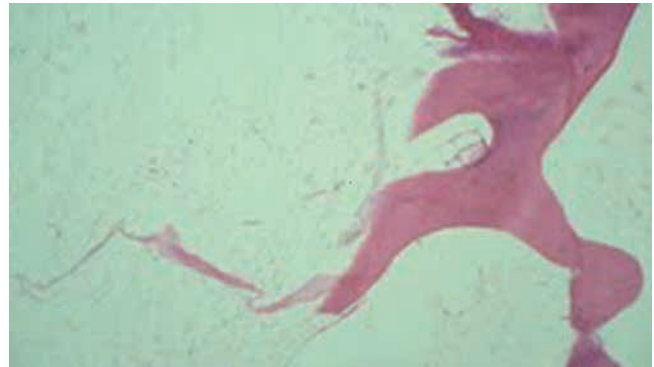

Fig. 2. — HE x16 mature lamellae, bone tissue and mature lipocytes.